

Toxicity Studies on Crude Leaf Extract of *Ocimum gratissimum* in Normoglycaemic and Diabetic Rats

Nelson I Oguanobi^{1*}, Chioli P Chijioke¹, Samuel I Ghasi¹, Francis I Ukekwe² and Keneth I Nwadike¹

¹Department of Pharmacology and Therapeutics, College of Medicine, Enugu Campus University of Nigeria, Nigeria

²Department of Histopathology, College of Medicine, Enugu Campus University of Nigeria, Nigeria

Research Article

Received date: 03/05/2019

Accepted date: 29/05/2019

Published date: 05/06/2019

*For Correspondence

Nelson I Oguanobi, Department of Pharmacology and Therapeutics, College of Medicine, Enugu Campus University of Nigeria, Nigeria.

E-mail: nelson.oguanobi@unn.edu.ng

Keywords: Toxicity, *Ocimum gratissimum*, Rats

ABSTRACT

Background: There is a growing interest in the medicinal value of extracts of *Ocimum gratissimum* plant. However, there is scanty data on the toxicity of extracts of this plant in experimental animals.

Objective: This study was aimed at evaluating the safety and the effects on organs of crude leaf extracts of *Ocimum gratissimum* in normoglycaemic and diabetic rats.

Methods: Freshly prepared leaf extracts of *Ocimum gratissimum* was administered on normoglycaemic and neonatal streptozotocine induced diabetic (n-STZ) rats. The animals were observed daily for clinical signs of toxicity throughout the period of study. At the end of the study, the animals were sacrificed after ether anesthesia. The kidneys, liver and a length of intestine were removed and examined for any pathologic changes due to treatment with the extract.

Result: At the extract dose of 300 mg/Kg body weight, no significant change was observed in all the biochemical parameters evaluated in the two groups following treatment with extract. Biochemical parameters were also similar in the normal and n-STZ rats. Sections of the small intestinal tissues of the animals treated with the extract showed enlarged intestinal Villi with nonspecific chronic inflammatory cell infiltration of the fibrovascular core. The liver tissues showed signs of mild to moderate vascular congestion which is otherwise unremarkable.

Conclusion: At the therapeutic dose used in this study the leaf extracts of *Ocimum gratissimum* appears to have no significant organ toxicity.

INTRODUCTION

Ocimum gratissimum (Linn), family Labiaceae, is an herbaceous plant commonly found in tropical Asia especially India. The plant also grows in West Africa. In Nigeria, it is found in the savannah and coastal areas. The leaves of the plant are used as a condiment in cooking. There is a growing interest in the medicinal value of extracts of *Ocimum gratissimum* plant^[1,2]. Essential oil extracted from four *Ocimum* species grown in Rwanda (i.e. *O. gratissimum*, *O. trichodon*, *O. canum* and *O. urticifolium*) have been reported to possess antimicrobial activity^[3]. A study in Trinidad and Tobago demonstrated antidiarrhea effects of aqueous leaf extracts of *Ocimum gratissimum* in experimental animals^[4]. Crude extracts of *Ocimum gratissimum* leaves have been used in the treatment of diabetes in southern Nigeria^[5] and tropical Asia^[6]. An initial study carried out in Jos, Nigeria in 2000, assessed the hypoglycaemic effect of methanolic extract of *Ocimum gratissimum* leaves in normal and alloxan-induced diabetic rats. The findings of this study showed that intraperitoneal injection of the extract (400 mg/kg) significantly reduced plasma glucose levels both in normal and diabetic rat by 56% and 68% respectively^[7]. A similar study in 2006 evaluated the hypoglycaemic property of orally administered doses of aqueous extract of *Ocimum gratissimum* in streptozotocin induced (type-1 model) diabetic rats. Administration of aqueous leaf extract produced a statistically significant reduction in plasma glucose concentration in the diabetic rats^[8]. This anti-diabetic property has been corroborated in the neonatal streptozotocin induced rat (n-STZ rat) which is considered to be a suitable experimental model of type-2 diabetes mellitus^[1,9-11]. Administration of doses of 100 mg/Kg, 200 mg/kg and 300 mg/kg in the neonatal streptozotocin induced rats resulted in a highly significant dose-dependent reduction

($p < 0.001$) at 2, 4 and 8 h time intervals^[4]. However, in both the normoglycaemic and hyperglycaemic rats blood glucose reduction was significantly more in the glibenclamide (5 mg/Kg) treated group at all-time intervals^[4]. The aqueous extract of *Ocimum gratissimum* elicited significantly greater reduction in blood glucose level than the ethanol extract in both normoglycaemic and diabetic rats^[4,11]. High doses of beta cell toxins like streptozotocin and alloxan induce insulin deficiency and type 1 diabetes mellitus with ketosis. However administration of calculated doses of these agents within the first week after birth, as used in this study, causes a partial destruction of beta cells mass and can be used to mimic the relative insulin deficiency state of type 2 diabetes mellitus without causing ketosis^[12]. Streptozotocin (STZ) is preferred to alloxan and other islet cell toxins because it has more specific beta cell cytotoxicity^[13]. It has been shown that there is some capacity of beta cell regeneration in neonatal rat pancreas, which is lacking in the adult rodent^[13,14]. The capacity of the cell regeneration in the Wistar strain decreases quickly during the first postnatal week and thereafter it is no longer significant^[9,10,13,15].

There is scanty data on the toxicity of extracts of this plant in experimental animals. This study was aimed at evaluating the safety and the effects on organs of crude leaf extracts of *Ocimum gratissimum* in normoglycaemic and diabetic rats.

MATERIALS AND METHODS

Plant Material

Fresh leaves of *Ocimum gratissimum* were collected from a garden in University of Nigeria Enugu Campus and were botanically authenticated at the Department of Botany University of Nigeria Nsukka, Nigeria.

Experimental Animals

Preparation of neonatal STZ-induced rat (n-STZ) model of type 2 diabetes mellitus

The neonatal rats with a body weight of 5.16 ± 0.29 g were treated with streptozotocin (Sigma, Aldrich Inc. USA) dissolved in citrated buffer (pH=4.3) by intraperitoneal injection at the dose of 80 mg/kg on the second day after birth^[9,10]. To achieve this 100 mg of streptozotocin was dissolved in 50 ml of citrated buffer giving a concentration of 2 mg/ml. Intraperitoneal administration of streptozotocin (STZ) was done using 100 IU/ml insulin syringes and needle. A total of 87 neonatal rats were treated with STZ. The blood glucose was monitored weekly using a One Touch® glucometer. After 6 weeks, diabetic rats having fasting plasma glucose level above 180 mg/dl were divided into groups for the study. The average weight at 6 weeks was 152 ± 3.16 g. The rats were described as “fasted” after 10-12 hours of overnight fast.

Normoglycaemic Animals

Adult wistar rats of either sex, six weeks old, weighing 120-180 g were used for the normoglycaemic arm of the study.

Housing

They were housed under standard condition in the Animal Research Unit of the Department of Pharmacology and Therapeutics, University of Nigeria Teaching Hospital Enugu. The animals were fed ad libitum on tap water and commercially available livestock feed (Unique feeds®, Farm Associates Nigeria Ltd. Enugu, Nigeria). The animals were fed on the “starter” mesh feed within the first two weeks of life; thereafter, the “grower/finisher” mesh feed was used until the end of the study.

Preparation of Extract

Fresh leaves of *Ocimum gratissimum* were kept in the oven at 80 °C for 10 mins to stop enzyme activity and then at 60 °C for 30 mins to dry. They were then air dried and ground into coarse powder. The coarse powder was subjected to aqueous and 70% ethanol extraction, separately, in a soxhlet apparatus for 10 h as follows:- Fifty grams of the powdered leaves were placed in the inner thimble of the soxhlet extractor apparatus. Water was passed through the inner thimble via a condenser with reflux system, from a round bottom flask containing 450 ml of distilled water and placed on a thermostatic heating mantle regulated at 100 °C. The alcohol extract was prepared in the same way as the aqueous extract with the exception of the use of 70% ethanol as solvent and soxhlet thermostat regulated at 60 °C.

After filtration through Whatman filter paper No.40, the filtrate was slowly evaporated to dryness with an electrothermal heating mantle regulated at 60 °C. The yield of the aqueous and ethanol extracts was 13.0% and 11.0% (weight for weight in terms of dried starting material), respectively. The extracts were stored in screwed cap vials at 4-8 °C until further use. The extracts were re-dissolved in distilled water when used and given orally through gastric intubations.

Administration of Extract

Three groups of fasted normoglycaemic rats were used (E1, E2, E3), each group consisting of five rats. Group E1 was given orally 300 mg/kg of aqueous extract. Group E2 was given orally 5 mg/kg of glibenclamide per day (positive control group). Group E3 was given orally 2 ml of normal saline (negative control group).

Another three groups of n-STZ diabetic rats (F1, F2, F3; each of five rats) were used. Group F1 was given orally 300 mg/kg of ethanol extract per day. Group F2 was given orally 5 mg/kg of glibenclamide per day (positive control group). Group F3

was given orally 2 ml of normal saline (negative control group). Oral administrations were done using stomach tube and was continued dally for three weeks. The serum urea, creatinine, total cholesterol and triglyceride as well as liver enzymes were measured at the beginning and at the end of the study. Blood sample were collected from the orbital plexus in heparinized tubes and plasma was separated within 30 mins of collection using a centrifuge for estimation of serum urea, creatinine, total cholesterol, and triglyceride using a Humalyzer GmbH® 2000 model auto-analyzer (Human GmbH., Cat. No. 18300; Germany), with filter sensitivity range of 340-630 nm. The animals were observed daily for clinical signs of toxicity throughout the period of the study. At the end of the study, the animals were sacrificed after ether anesthesia. The kidneys, liver and a length of intestine were removed and examined for any pathologic changes due to treatment with the extract.

Histological Preparations

Segments of the excised organs were immersed in formylsaline for seven days for fixation. The fixative for the samples was changed daily. After fixation, the samples were dehydrated in a series of ethanol concentrations (70%, 90%, 95%, 100%), cleared in toluene and then embedded in Paraplast. Blocks were cut at 5-7 µm. Sections were then dehydrated in a series of ethanol concentrations (100%, 95%, 90%, 70%), stained in Haris haematoxylin for 6 mins and concentrated in 1% aqueous eosin for 1 min. Sections were then dehydrated in ethanol as previously, cleared in xylene and mounted in Depex. Stained sections were identified with coded labels and examined independently by two pathologists who were unaware of the identity of the stained slides and photographed on a Zeiss Axioskop 40 Compound Photomicroscope. Whenever disparity was observed in the reports of the pathologists, a third opinion was sought.

Data Analysis

Data were presented as mean ± Standard Error of Mean (SEM). Differences between groups were compared using analysis of variance and Student t-test. All statistical analyses were carried out using the statistical packages for social science (SPSS Inc. Chicago Illinois) software version 11.0. Statistical test with probability values less than 0.05 were considered statistically significant.

RESULTS

Biochemical Parameters

The effect of repeated daily administration of the aqueous extract of *Ocimum gratissimum* for three weeks in normal and n-STZ rats are presented in **Tables 1 and 2**.

At the extract does of 300 mg/Kg body weight, no significant change was observed in all the biochemical parameters evaluated in the two groups following treatment with extract. Biochemical parameters were similarly unchanged in the normal and n-STZ rats treated with ethanol extract.

Table 1. Comparison of the biochemical parameters in n-STZ rats before and after prolonged administration of aqueous extract of *Ocimum gratissimum*.

parameters	Mean (SEM)		T-test	p-value
	Before	After		
	Treatment	Treatment		
Total cholesterol	2.80 (0.371)	2.92 (0.423)	1.028	0.318
Triglyceride	1.10 (0.477)	1.04 (0.570)	0.93	0.365
Creatinine	98.24 (5.75)	96.61 (4.64)	0.549	0.54
Urea	5.4 0 (0.686)	4.73 (0.516)	0.226	0.823
SGOT (AST)	59.11 (6.27)	57.23 (5.76)	0.204	0.841
SGPT (ALT)	26.56 (1.25)	26.00 (1.41)	1.192	0.25

Table 2. Comparison of the biochemical parameters in normal rats before and after treatment with aqueous extract of *Ocimum gratissimu*.

parameters	Mean (SEM)		T-test	p-value
	Before	After		
	Treatment	Treatment		
Total cholesterol	2.64 (0.417)	2.65 (0.431)	0.123	0.903
Triglyceride	1.33 (0.555)	1.23(0.601)	1.357	0.184
Creatinine	102.88 (4.066)	98.56 (5.604)	1.494	0.156

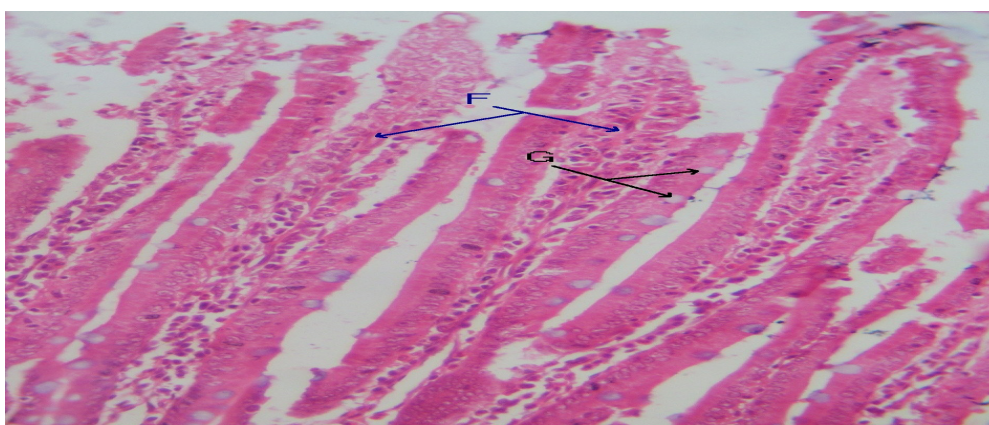
Urea	4.86 (0.755)	4.83 (0.501)	0.06	0.593
SGOT (AST)	50.42 (3.27)	47.61 (4.08)	1.368	0.192
SGPT (ALT)	26.75 (1.342)	25.69 (1.793)	0.627	0.535

Histopathological Findings

During the daily oral administration of the leaf extracts of *Ocimum gratissimum* for 3 weeks at the dose of 300 mg/kg body weight, there was no mortality in all the groups treated. Gross examination of the organs harvested did not reveal any pathological changes due to the treatment with the extract.

General histopathological evaluation of the organs revealed mild changes in the intestine and the liver. Sections of the small intestinal tissues of the animals treated with the aqueous and ethanol extracts showed enlarged intestinal Villi with nonspecific chronic inflammatory cell infiltration of the fibrovascular core (F). The Goblet cells (G) appear normal, (Figure 1). The liver tissues showed signs of mild to moderate vascular congestion which is otherwise unremarkable, (Figure 2). Figure 3 shows photomicrographs of the control and test kidney tissues showing normal renal parenchyma with no remarkable histologic changes.

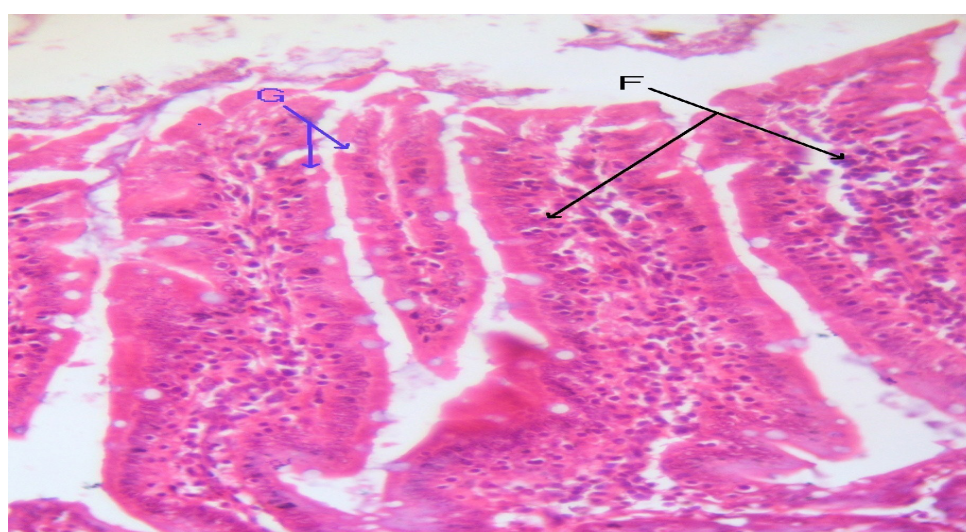
(a) Untreated rat



Magnification 40X

Above is a photomicrograph of the Control Small Intestine showing normal Intestinal Villi with normal thin Fibrovascular core (F) and Goblet cells (G).

(b) Extract treated rat

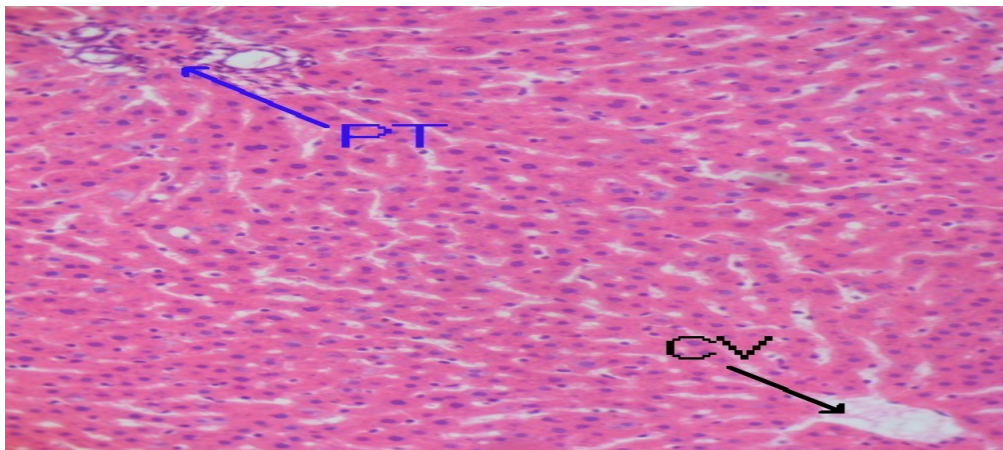


Magnification 40X

Above is a photomicrograph of the Test Small Intestine showing enlarged Intestinal Villi with Intense Nonspecific Chronic inflammatory cell infiltration of Fibrovascular core (F). The Goblet cells (G) appear normal.

Figure 1. Histological sections of the small intestine of rats (a) not treated with aqueous extract, (b) extract treated.

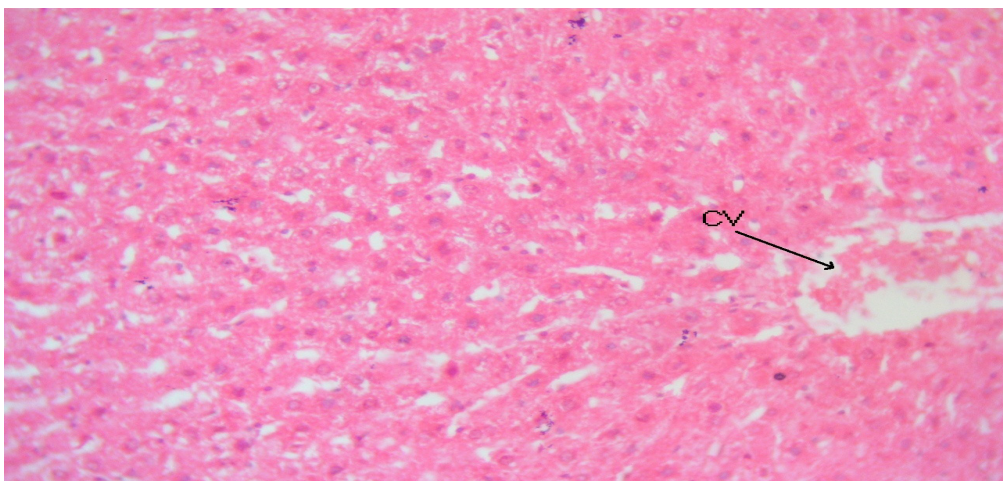
(a) Untreated rat



Magnification X 40

Above is a photomicrograph of the control Liver showing normal Liver parenchyma with Portal Tract (PT) and Central Vein (CV) in view.

(b) Extract treated

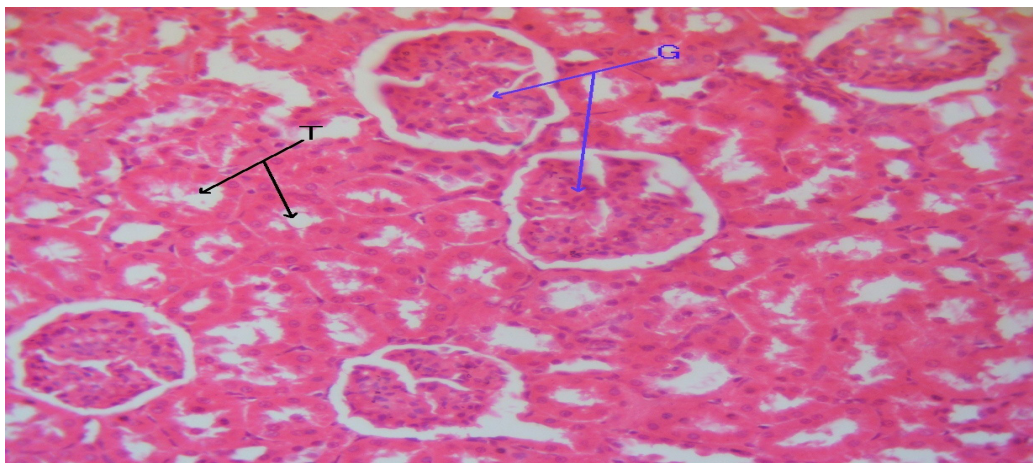


MagnificationX40

Above is a photomicrograph of the Test Liver showing mild to moderate vascular congestion.

Figure 2. Histological sections of the liver of rats (a) not treated with aqueous extract, (b) extract treated.

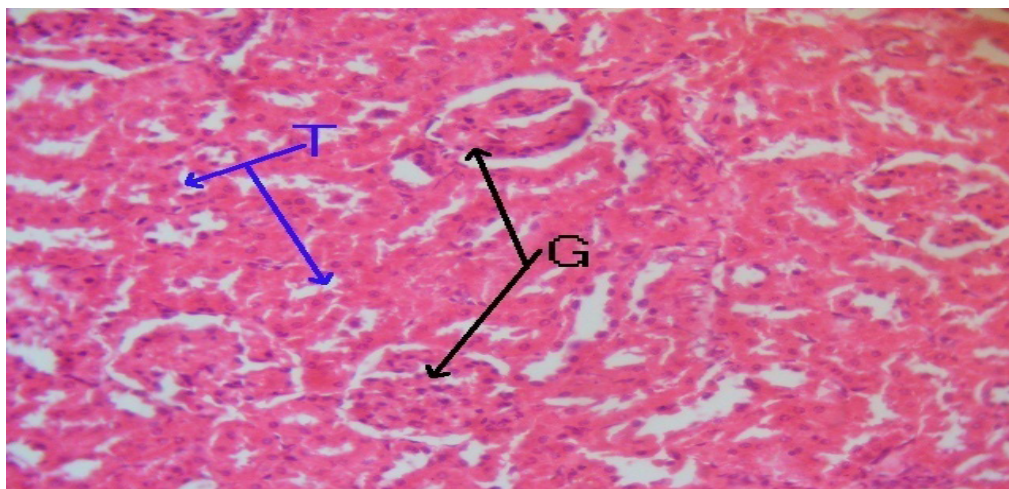
(a) Untreated rat



Magnification 40X

Above is a photomicrograph of the Control Kidney showing normal renal parenchyma with Tubules (T) and Glomeruli (G).

(b) Extract treated rat



Magnification 40X

Above is a photomicrograph of the Test Kidney showing renal parenchyma with no remarkable histologic changes.

Figure 3. Histological sections of the kidney of normal rats; (a) not treated with extract, (b) extract treated,

DISCUSSION AND CONCLUSION

Biochemical and Histopathological Effects of *Ocimum gratissimum*

Hypercholesterolaemia and hypertriglycaemia have been reported to occur in streptozotocin induced diabetes rats [16-18]. Under normal circumstances, insulin activates the enzyme lipoprotein lipase and hydrolyses triglycerides. In insulin deficient subjects, this process is impaired resulting hypertriglyceridaemia. However in the relative insulin deficiency state that occurs in neonatal streptozotocin type-2 diabetic rat model, hypertriglyceridaemia is not a characteristics feature because activation of lipoprotein lipase occurs at relatively lower plasma insulin concentration. This explains the findings by this study of an absence of any significant difference in the plasma cholesterol and triglyceride in n-STZ rats and normal rats.

Three weeks oral administration of the extracts in the normal and n-STZ rats produced no significant effect on the plasma cholesterol and triglyceride. The absence of any significant difference in the baseline plasma level of liver enzymes and serum urea and creatinine in the normal and n-STZ rats suggest that the liver and kidneys may not be significantly deranged in the neonatal streptozotocin rat model. Administration of the extract did not cause any significant derangement in these parameters indicating its relative safety.

The histopathological findings in the intestine and liver of increased villous spaces and presence of numerous goblet cells are indicative of the stimulatory effect of *Ocimum gratissimum* on gastrointestinal glands secretion. This action may, in part, explain the reported insulin secretagogue effect of the extract in diabetic animal models. The infiltration of inflammatory cells

in the intestinal mucosa is likely due to its irritant or allergic effect on the bowel. Previous studies have reported significant hypoglycaemic activities of crude leaf extracts of *Ocimum gratissimum* in diabetic animal models at doses ranging from 100-200 mg/kg body weight.

At the therapeutic dose used in this study the extract appears to have no significant organ toxicity. This plant is widely distributed and its common use by people as a condiment in cooking suggests a relative lack of toxicity. The findings of this study underscore the potential medicinal usefulness of extracts of *Ocimum gratissimum*.

CONFLICT OF INTEREST

The authors have no potential conflict of interest.

REFERENCES

1. Oguanobi NI, et al. Anti-diabetic effect of crude leaf extracts of *Ocimum gratissimum* in neonatal streptozotocin-induced type-2 model diabetic rats. *International Journal of Pharmacy and Pharmacology*. 2012;4:77-83.
2. Onajobi FD. Smooth muscle contracting lipid soluble principles in chromatographic fraction of *Ocimum gratissimum*. *J Ethnopharmacology*. 1986;18:3-11.
3. Janssen AM, et al. Antimicrobial activities of some *Ocimum* species grown in Rwanda. *J Ethnopharmacology*. 1989;12:57-63.
4. Offiah VN and Chikwendu UA. Antidiarrhoeal effects of *Ocimum gratissimum* leaf extract in experimental animals. *J Ethnopharmacology*. 1999;68:327-330.
5. Igoli JO, et al. Traditional medicine practices amongst the Igede people of Nigeria. Part II. *Afr J Tradit Complement Altern Med*. 2005;2:134-152.
6. Prakash P and Gupta N. Therapeutic uses of *Ocimum Sanctum* Linn (Tulsi) with a note on eugenol and its pharmacological actions: A short review. *India J Physiol Pharmacol*. 2005;49:125-131.
7. Aguiyi JC, et al. Hypoglycaemic activity of *Ocimum gratissimum* in rats. *Fitoterapia*. 2000;71:444-446.
8. Egusie UG, et al. Safety and hypoglycaemic properties of aqueous leaf extract of *Ocimum gratissimum* in streptozotocin induced diabetic rats. *Niger J Physiol Sci*. 2006;21:31-35.
9. Junod A, et al. Diabetogenic action of streptozotocin: Relationship of the dose to metabolic response. *J Clin Invest*. 1969;48:2129-2139.
10. Blondel O, et al. Relation of insulin deficiency to impaired insulin action in NIDDM adult rat given strptozotocin as neonates. *Diabetes*. 1989;38:610-617.
11. Oguanobi NI, et al. Effects of aqueous leaf extract of *Ocimum gratissimum* on oral glucose tolerance test in type-2 model diabetic rats. *Afr J Pharm Pharmacol*. 2012;6:630-635.
12. Portha B, et al. The rat models of non- insulin dependent diabetes induced by neonatal streptozotocin. *Diabetes Metab*. 1989;15:61-75.
13. Bonner-Weir S, et al. Responses of neonatal rat islets to streptozotocin; Limited B-cell regeneration and hyperglycaemia. *Diabetes*. 1981;30:64-69.
14. Weir GC, et al. Experimental reduction of B-cell mass: Implications for the pathogenesis of diabetes. *Diabetes Metabo Rev*. 1976;2:125-161.
15. Portha B, et al. Chemical diabetes in the adult rat as the spontaneous evolution of neonatal diabetes. *Diabetologia*. 1979;17:371-377.
16. Sharma SR, et al. Hypoglycaemic, antihyperglycaemic and hypolipidaemic activities of caesalpinia bonducella seeds in rat. *J Ethnopharmacol*. 1997;58:39-44.
17. Choi JS, et al. Improvement of hyperglycaemia and hyperlipaemia in stretozotocin diabetic rats by a methanolic extract of *Prunus davidiana* stems and its mean component pruning. *Planta Med*. 1991;57:208-211.
18. Sharma SR. Hypoglycaemic and hypolipidaemic effects of *Cinnamomum tamala* nees leaves. *Indian J Exp Biol*. 1996;34:372-374.