

A Case Report of Lipomyelomeningocele Causing Equinovarus

Chengcai Hou*

Department of Hand, Foot and Ankle Surgery, Zaozhuang Municipal Hospital, Shandong, China

Case Report

Received: 06-June-2022, Manuscript No. jmahs-22-56091; **Editor assigned:** 10-June-2022, Pre QC No. jmahs-22-62369 (PQ); **Reviewed:** 22-June-2022, QC No. jmahs-22-56091; **Revised:** 29-June-2022, Manuscript No. jmahs-22-56091 (R); **Published:** 08-July-2022, DOI: 10.4172/2319-9865.11.4.001.

***For Correspondence:**

Chengcai Hou, Department of Hand, Foot and Ankle Surgery, Zaozhuang Municipal Hospital, Shandong, China

E-mail:

houchengcai333@163.com

Keywords:

Lipomyelomeningocele; Equinovarus; High arched foot Osteotomy correction; Soft tissue loosening; Calcaneocubic joint fusion

ABSTRACT

Background

Lipomyelomeningocele (LMM) is a congenital factor that causes clubfoot. This disease often develops into adulthood and often has rigid deformities. This is the most difficult orthopedic and functional reconstruction surgery.

Case presentation

We report case of stiff club foot caused by Lipomyelomeningocele (LMM). Through osteotomy correction and Soft tissue loosening, clubfoot deformity was corrected and good results were achieved.

Conclusion

The use of osteotomy correction technology combined with Soft tissue loosening to treat adult stiff clubfoot can correct the deformity and restore the shape of the foot and ankle. The effect is definite and it is worthy of popularization and application.

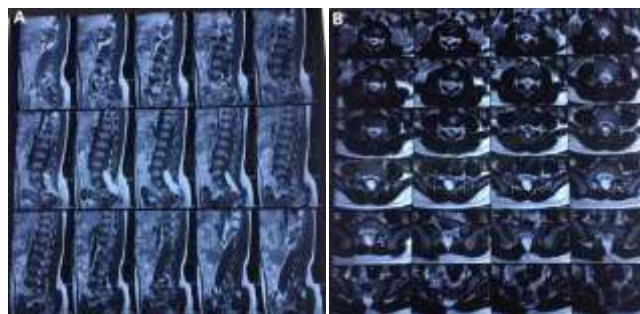
INTRODUCTION

Equinovarus is one of the most common malformations in the motor system [1], and adult rigid equinovarus is the most difficult category of surgical orthotics and functional reconstruction [2]. Equinovarus occurrence reason is caused by innate or acquired a variety of factors, congenital lesions in fetal period of primary development is mainly due to the limb, evolved into the Equinovarus deformity, the day after tomorrow is mainly due to the nervous peroneus commun is injury sequela, foot ankle trauma sequela, stroke and cerebral hemorrhage sequelae, lesions caused by polio. This case is a congenital Equinovarus deformity due to lipomyelomeningocele which is reported as follows.

CASE PRESENTATION

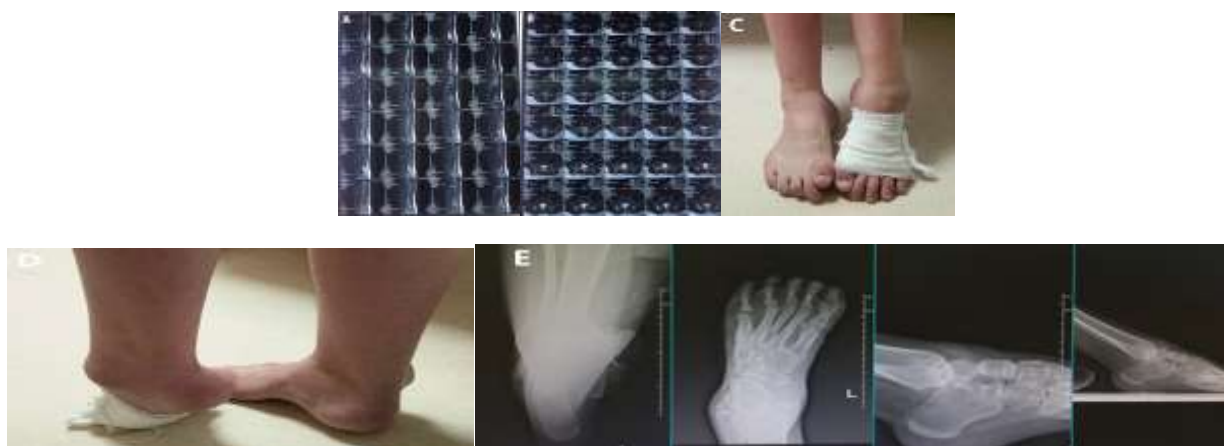A 20-year-old male patient was diagnosed with congenital neural tube malformation-Lipomyelomeningocele (LMM) 10 years ago when he was found to have bipedal varus and decreased muscle strength (Figure 1).

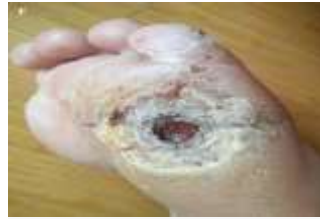Figure 1. Ten years ago, lumbar MRI showed: (A and B) fatty myelomeningocele pressing on the spinal cord.



He underwent spinal cord surgery at that time. Six years after the operation, the left foot varus was significantly worsened, the left ankle flexion and extension was limited, the ankle joint plantar flexion was 70°, and the average range of motion was 10° (plantar flexion 10°-back extension 0°); tibialis anterior muscle and fibulamuscle strength level 0, tibialis posterior muscle strength level 2, Raise the medial longitudinal arch, plantar ulceration, sphincter bladder function paralysis, and catheterization bag for 5 years (Figure 2).

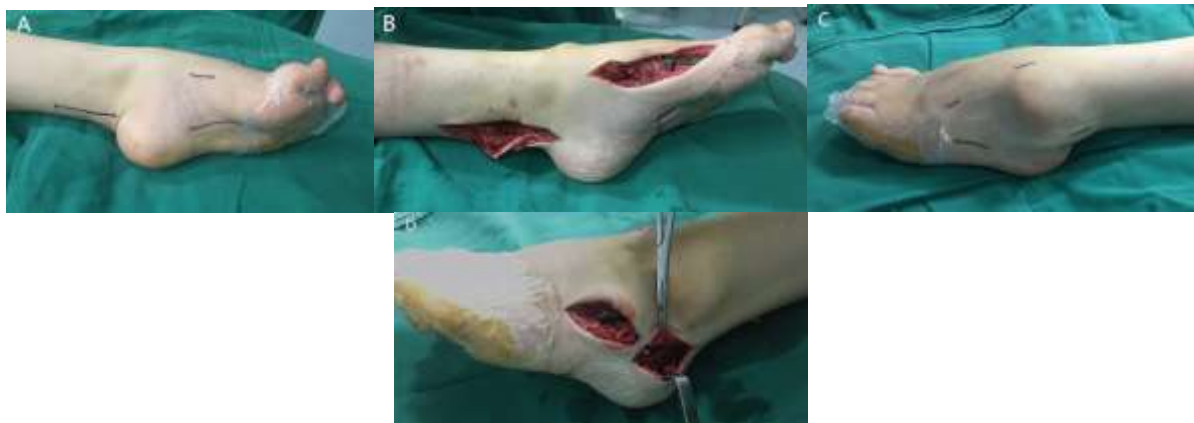Figure 2. Lumbar MRI reexamination after spinal cord related surgery showed : (A and B) left fat mass was found in the spinal cord; (C and D) X ray of both feet showed: left and right heel pronation, left food plantar flexion; (E) Heel pronation in the left heel loading long axis position; Weight bearing position of left ankle showed plantar flexion of ankle, plantar flexion of first metatarsal; (F) Persistent plantar ulcers.





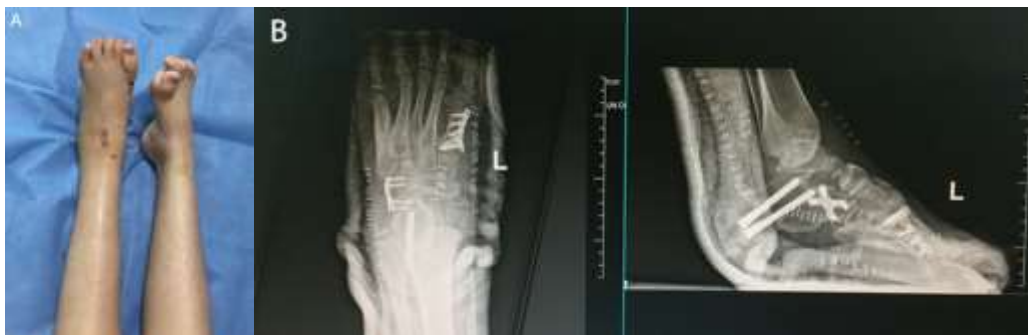Use general anesthesia. Patient in supine position. First, a small longitudinal incision was made on the medial side of the Achilles tendon, and a sharp knife was used to cut the tendon vertically. The Achilles tendon was released in the shape of "Z". After proper pulling, the arteries and veins and nerves of the posterior tibial were separated for protection, and the soft tissue and the posterior tibial joint capsule were released. The insertion point of the posterior tibial tendon was cut through the medial foot incision, and the tendon was extracted before the ankle to prepare for the external displacement of the posterior tibial tendon. The plantar medial incision was made to expose the plantar aponeurosis, and "Z" was released to suture the skin. The dorsal incision of the first metatarsal base was made, the skin was cut subcutaneously, the first metatarsal base was exposed, and the first metatarsal base was cuneate osteotomy, fixed with 6-hole "T" type plate and screw, and the internal arch of the foot was reduced. Make an incision at the calcaneocuboid joint on the dorsolateral side of the foot, cut the skin subcutaneously, expose the calcaneocuboid joint, remove the cartilage surface, and expose the fresh bone surface, "X" fix with steel plate and screw to correct the foot adduction. The lateral incision of the calcaneus was made, the skin was cut subcutaneously, the external side of the calcaneus was exposed, and the bone knife was osteotomized and externally removed, and fixed with a 4.5 mm hollow screw to correct the calcaneal varus. Intraoperative fluoroscopy showed that the position of steel plate, screw and hollow screw was good and the length was appropriate. The incision was made at the lateral calcaneus, the skin was cut subcutaneously, the peroneus brevis was separated, the tendons of the anterior ankle and the posterior tibial tendon were moved and sutured to strengthen the eversion force, the muscle balance was observed during the operation, the varus of the foot, high arch and plantarsal flexion were corrected, the wound was rinsed, the layer by layer was sutured, and the back extension was fixed with plaster. The operation was successful, the anesthesia was satisfactory, and the patient was returned to the ward after the operation (Figure 3)

Figure 3. Intraoperative findings: (A) Achilles tendon, posterior tibial tendon insertion, plantar aponeurosis incision;(B) Release of the Achilles tendon "Z", release of the plantar aponeurosis, wedge osteotomy of the base of the first metatarsal, and reduction of the medial longitudinal arch;(C) calcaneocuboid joint, peroneal tendons and anterior ankle incisions;(D) Fusion of calcaneocuboid joint and calcaneal valgus osteotomy.



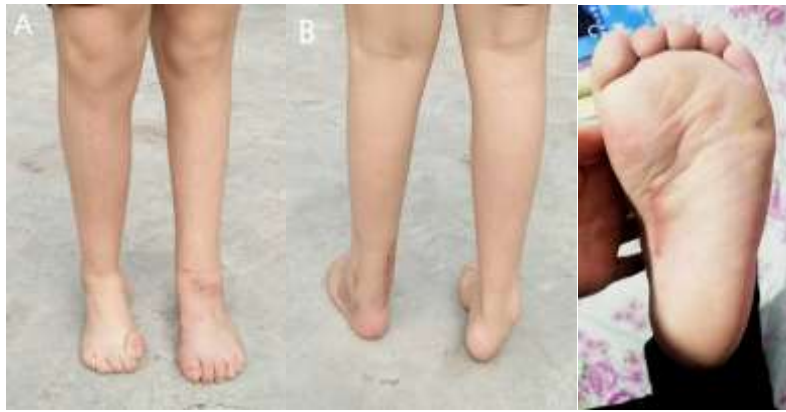On the 7th day after the surgery, after the inflammatory swelling subsided, patient is pain to perform active and passive activity. After the suture removal through the incision on the 14th day after the surgery, the knee joint flexion and extension on the bedside were performed to train muscle strength (Figure 4).

Figure 4. Postoperative results showed that: (A) the left foot Equinovarus deformity was corrected with A beautiful appearance, and the right foot deformity was not operated on; (B) Postoperative X-ray examination.



On the 35th day after the operation, patient is required to walk with two crutches or Help line device without weight. 60 days after surgery, partial weight-bearing walking exercise was started. After 90 days of surgery, walk with full weight and resume daily life (Figure 5).

Figure 5. (A) Three months after operation, both feet orthotopic film;(B) the posterior position of both feet was taken, and Left foot deformity was corrected;(C) Plantar ulcer healing 3 months after surgery.



DISCUSSION

Equinovarus is mainly divided into two types: congenital and acquired; Congenital Equinovarus caused by bad growth is mainly due to the Achilles tendon and shortening of the triceps surae, acquired the Equinovarus mainly because the ankle back extensor group, the outer most or complete loss of muscle strength, Triceps of the lower leg and most of the varus muscles strength is normal, lead to the Achilles tendon contracture, strephenopodia continuously, which in turn leads to the ankle, talonavicular joint, subtalar joints, with roll displacement of joints, foot ankle joints, ligaments and other soft tissue contracture of the joint capsule around, adhesion, secondary deformity. It is mainly caused by the following reasons, such as congenital musculoskeletal malformation, infection, osteomyelitis [3], congenital equinovarus failure in treatment, traumatic fracture and other reasons leading to the sequela of crus osteofascial compartment syndrome [4]. Extensive scar on the ankle caused by burns [5], nervus peroneus communis injury [6], lumbosacral spina bifida and poliomyelitis sequela [7]. Clinical manifestations are mainly: the talus pancake, the neck of talus shorter distortion, cartilage degeneration and the metapedes plantar flexion, varus and intorsion [8], navicular bone deformation dislocation after full high arch, supination deformity, propodeon adduction [9], the medial plantar and back skin, subcutaneous tissue, the fascia, tendon, articular capsule, blood vessels, nerves, such as soft tissue contracture, ankle lateral corresponding soft tissue hypoplasia, relaxation or destroy [10].

At present, the understanding of congenital equinovarus disease is relatively mature, and the therapeutic effect is remarkable. The case was a equinovarus caused by congenital lipomyelomeningocele. Lipomyelomeningocele (LMM) is Neural Tube Defects (NTD), the disease is due at 18 ~ 28 d, premature epithelial ectoderm from neural ectoderm, mesenchymal cells into developing neural tube, the formation of fat affect the spinal cord, the fat through the catheter into the subcutaneous tissue, the disease often occurs in women, more than 30% of patients can be characterized by abnormal skin such as mass, fur sinus, vascular malformation, etc., all suggest that the patient may have abnormal neural tube development such as LMM. It can also be manifested as nerve damage, such as Tethered Cord Syndrome (TCS), such as defecation and urination dysfunction, lower limb motor sensation disorder, sexual dysfunction, etc. [11]. Without timely intervention after the diagnosis of LMM, 90% of patients will develop irreversible progressive nerve damage [12]. In many studies, through the inference of the natural history of this disease, it was believed that: most patients' symptoms gradually aggravated with time, including lower limb movement disorder, muscle weakness, equinovarus and high arch, and the symptoms gradually aggravated, and at this time, surgery was the only effective way to treat the symptoms at present; However, postoperative dysfunction

of urine and feces, especially bladder function, cannot be improved [13]. Long-term follow-up observation is needed after LMM operation to monitor the occurrence of LMM. LMM can occur months to years after surgery, with an incidence of 5% ~ 50%, manifested by gradual aggravation of original symptoms or new symptoms, such as pain, incontinence, sexual dysfunction, and weakness of both legs. After the postoperative stability of the patient's symptoms, new neurological symptoms or aggravation of the original symptoms should be evaluated for the presence of LMM [14]. MRI examination is an important evidence to determine the presence or absence of LMM. Based on the presence or absence of lower spinal cord, syringomyelia, etc., the patient must be combined with clinical symptoms to make a correct judgment.

Equinovarus on the basis of the extent of the ankle joint stiffness is divided into soft and rigid, and the deformation of different age stages present different properties, Equinovarus deformity can press "qin SiHe equinovarus parting" description: I degrees, with the outside of planta weight; II degrees, use the front edge of the fourth and fifth metatarsal of weight; III degrees, sufficient varus, internal rotation, toes pointing to the rear foot heart up, walking with foot dorsal weight. The case is rigid type II degrees of deformity, needing delay correction, the correction to correct the strephenopodia inward turning talipes cavus, to correct the plantar flexion.

During the treatment, this case adhered to the principle of moderate weight-bearing walking exercise [15] and "two lines and three balances along the way". "All the way", that is, walking, walking in the treatment, walking in the treatment; the "two lines" are the "negative gravity line of the lower extremity" and the "joint line" of the hip, knee and ankle. The line and correction of other local malformations must finally meet the requirements of the recovery of the two lines of the lower extremity." Three-balance" is the "static balance and dynamic balance, the balance between the rigidity of fixed apparatus and the strength of bone healing, the balance between body and mind" in the process of limb reconstruction. By surgical treatment, malformations can be corrected, the shape of the ankle can be restored, and the affected foot plantar and painless weight-bearing walking can be made, so that the patients have high satisfaction [16].

CONCLUSION

Osteotomy correction technology combined with soft tissue loosening is an effective method for the treatment of adult stiffness clubfoot. This method can correct the foot shape to the plantar foot and walk with weight. The effect is positive. At present, there are no large-scale clinical studies, and only few reports, but the effectiveness of correction methods still needs to be further studied.

Ethics approval and consent to participate

All patients or their relatives provided informed consent, and the study was approved by the ethical committee of Zaozhuang Municipal Hospital.

Competing interests

The author declare that they have no competing interests

Funding

NO

Authors' contributions

Chengcai Hou designed the study, performed the surgery, collected data, analyzed statistics, and wrote the article.

ACKNOWLEDGEMENT

The authors are grateful to the subjects who participated in the study and to the physicians' assistance in this study.

REFERENCES

1. Luan B, et al. Significance of manipulation technique orthopedic procedure for Ilizarov technique in correcting equinovarus. *Guizhou pharmaceutical*, 2015;39: 523-525.
2. Liu M, et al. Diagnosis and treatment of stiff equinovarus deformity. *J Am Acad Orthop Surg*. 2015;21: 1011-1014.
3. Dhar S. Ilizarov external fixation in the correction of severe pediatric foot and ankle deformities. *Foot Ankle Clin*. 2010; 15:265-285.
4. Qin S, et al. Limited orthopedic surgery and Ilizarov technique in the treatment of juvenile congenital equinovarus. *Chin J of Reconstr Surg*. 2012; 26: 31-35.
5. Zhang Z, et al. Ilizarov technique in the treatment of equinovarus deformity after burns. *Chin J of Reconstr Surg*. 2018; 32:178-181.
6. Aktuglu K, et al. Monofocal bone transport technique for bone defects greater than 5 cm in tibia: our experience in a case series of 24 patients. *Injury*. 2016; 47: S40-S46.
7. Nomura I, et al. Correction of a severe poliomyelitic equinovarus foot using an adjustable external fixation frame. *J Foot Ankle Surg*. 2014, 53: 235-238.
8. Eidelman M, et al. Treatment of arthrogryptic foot deformities with the Taylor Spatial Frame. *J Pediatr Orthop*. 2011; 31: 429-434.
9. Brodsky JW. The adult sequelae of treated congenital club-foot. *Foot Ankle Clin*. 2010;15:287-296.
10. Devadoss A, et al. Differential distraction for relapsed clubfoot deformity in children. *J Orthop Surg(Hong Kong)*. 2010;18: 342-345.
11. Wykes V, et al. Asymptomatic lumbosacral lipomas-a natural history study. *Childs Nerv Syst*. 2012; 28: 1731-1739.
12. Motah M, et al. Management of tethered cord syndrome in adults: a case report in Cameroon. *Pan Afr Med J*. 2014; 17: 217.
13. DUSHI G, et al. Urodynamics score in children with lipomyelomeningocele: a prospective study. *J Urol*. 2011; 186: 655-659.
14. LEW S M, et al. Tethered cord syndrome: an updated review. *Pediatr Neurosurg*, 2007; 43: 236-248.
15. Chen JW, et al. Joint drafting and Ilizarov technique in the treatment of knee and ankle joint deformity caused by calf muscle contracture. *Chin J Tissue Eng Res*. 2008; 12:7636-7640.
16. Saghieh S, et al. The correction of the relapsed club foot by closed distraction. *Strategies Trauma Limb Reconstr*. 2010;5: 127-135.