

RESEARCH AND REVIEWS: JOURNAL OF MEDICAL AND HEALTH SCIENCES

A Clinico - Pathological Study of Ovarian Lesions.

Vijay Kumar Bodal^{1*}, Tanu Jindal¹, Manjit Singh Bal¹, Ranjeev Bhagat¹, Sarbhjit Kaur², Ninder Mall¹, Anikita Goel¹, and Priyanka Goyal¹.

¹Department of Pathology, Government Medical College, Patiala, Punjab, India.

²Department of Gynecology and Obstetrics, Government Medical College, Patiala, Punjab, India.

Research Article

Received: 09/12/2013
Revised: 19/01/2014
Accepted: 29/01/2014

*For Correspondence

Department of Pathology,
Government Medical College,
Patiala, Punjab, India.

Keyword: Endometriosis,
Krukenberg tumour, ovarian
tumours, serous
cystadenocarcinoma.

ABSTRACT

Ovarian lesions frequently form a pelvic mass and are associated with abnormal hormonal manifestations. Clinically and surgically they potentially mimic ovarian neoplasms but pathologically they can be classified into non neoplastic cysts, inflammation and neoplasms. Objective of the study was to determine the nature, frequency and distribution of ovarian lesions and to correlate their clinical findings with the histo-pathological features. The specimens of ovary from 150 patients were subjected to critical gross as well as histo-pathological study. Routine paraffin sections with H & E were seen. The clinical as well as histological findings were compiled on proforma and subjected to analysis. A total of 150 cases of non-neoplastic and neoplastic lesions were included. Non-neoplastic were more common (60%) than neoplastic lesions (40%). The commonest non-neoplastic lesion was luteal cyst followed by follicular cyst and endometriosis. Among the neoplastic tumours, 75% were benign; 1.66% borderline and 23.34% malignant. Surface epithelium tumours formed the maximum number followed by germ cell and sex cord stromal tumors. Only 1 case (1.67%) of non-ovarian metastatic (Krukenberg tumour) tumor was diagnosed. Benign serous cysts were the commonest benign tumours and serous cystadenocarcinoma was the commonest malignant tumour. Single case of borderline malignancy was included in the surface epithelial tumors category. Ovarian lesions pose many challenges. Gross features provide useful diagnostic clues. A specific diagnosis can usually be made on routinely H & E stained slides.

INTRODUCTION

Ovary is normally a partially cystic structure and the risk of carcinoma developing in these cysts is negligible ^[1]. Various inflammations of ovary are non-specific inflammation, granulomatous infections, autoimmune oophoritis and eosinophilic perifolliculitis. Intrinsic inflammations of the ovary (oophoritis) are uncommon, usually accompanying tubal inflammation. Rarely, a primary inflammatory disorder involving ovarian follicles (autoimmune oophoritis) occurs and is associated with infertility ^[2]. Ovarian tumours arise from a) surface epithelium b) the germ cells c) stroma of the ovary ^[2]. Based on the histological cell of origin, a morphological classification of ovarian tumours - Primary and secondary (metastatic) or benign, borderline and malignant is recognised by International Federation of Gynaecology and Obstetrics (FIGO) and World Health Organisation (WHO) ^[3, 4]. Of all the primary ovarian tumours about 70 to 80% are of epithelial origin (80% benign and 20% malignant), 10% of stromal origin and 5% of germ cell origin while remainder fall into other groups ^[5]. Carcinoma of the ovary ranks third among female genital carcinomas, occurring next to cervix and endometrium in frequency. ^[6] The ovarian cancer accounts for 3% of all malignancies and 6% of deaths from cancer in women, and almost one third of invasive malignancies of the female genital organs. ^[7] With the exception of germ cell tumours and special sex cell tumours (which predominate in prepubertal children and young adults), most of the primary ovarian neoplasms are commonly found in the women aged 40-60 years. Benign tumours and tumours with low malignant potential peak usually between 20-40 years; whereas invasive carcinoma are seen more frequently between 50-70 years. ^[8] Most of the

ovarian tumours are non-functional and tend to produce relatively mild symptoms until they reach a large size. Malignant tumors have usually spread outside the ovary by the time a definitive diagnosis is made. Some of these tumors, principally epithelial tumors, tend to be bilateral. gastrointestinal tract symptoms like abdominal pain, distension, urinary complaints due to compression by the tumor or cancer invasion, and vaginal bleeding are the most common symptoms. The benign forms may be entirely asymptomatic and occasionally are found unexpectedly on abdominal or pelvic examination or during surgery^[4]. The ovary may be the site of primary disease as well as of disseminated lymphoma. The carcinoma of the ovary, thus being a silent lesion and the site of this ovarian tumour renders it inaccessible to simple methods of anatomical diagnosis such as smears, biopsy and curettage. It warns us to beware of ovarian neoplasia-benign or malignant.^[9]

MATERIALS AND METHODS

The study was conducted on 150 resected specimen of ovaries received in the department of pathology, Government Medical College, Patiala. These included surgically resected ovaries, either as a part of total abdominal hysterectomy with bilateral salpingo-oophorectomy or as a clinically diagnosed ovarian lesions. Specimens were fixed in 10% formalin, grossly examined; paraffin sections & slides were prepared and stained with haematoxylin and eosin & some special stains. After this sections were examined under light microscope and correlated with histopathological findings.

RESULTS

Out of the total 150 cases studied, 60 (40%) cases were ovarian tumours and 90 (60%) cases were non neoplastic lesions (Table-1). Among non neoplastic lesions corpus luteal cyst was more common comprising of 48 cases; 53.33% of total non neoplastic lesions. Second highest group was follicular cyst having 30 cases; 33.33% of total neoplastic lesions. About 12 cases of endometriosis; 13.34% was noted (Table-2). Majority of the non neoplastic lesions were unilateral cystic tumours and all the lesion were below 10 cms in size. Non neoplastic lesions occurred in all age group, in present study majority of the incidence of non neoplastic lesion were seen in the age group of 20-39 years of age group (Table-3).

Majority of the tumours were benign constituting 75%, followed by malignant 23.34% and borderline tumours 1.66% (Table-4). The mode of presentation of neoplastic lesions were abdominal mass in (69.33%) followed by abdominal pain (33.3%), postmenopausal bleeding (13.33%), Abnormal bleeding per vaginal (8.33%) ascites (3.33%) and low backache (1.67%) (Table-5). The surface epithelial tumours formed the largest group (71.66%) followed by germ cell. tumours (23.33%), stromal tumours (3.34%) metastatic tumours (Krukenberg tumour) were 1.67% (Table-6). Bilaterality was found in 6 cases (10%) of which papillary serous cystadenocarcinoma was the most common tumour noted. The tumours varied in size. The largest tumour was malignant mixed germ cell tumour measuring 26x24x20 cm and smallest tumour was benign mucinous cystadenoma measuring 3x2x2 cm. The commonest surface epithelial tumours were Serous cyst adenomas (31.66%) followed by mucinous cystadenoma (26.67%). The occurrence of malignancy was seen more in serous tumours (5%) as compared to mucinous tumours (3.33%). One cases of endometrioid carcinoma was noted. Mature cystic teratoma was the commonest histological type among germ cell tumours. One case of mixed germ cell tumour was noted having a rare combination of immature teratoma and yolk sac tumour. The group of Sex-cord stromal tumour was having one case of granulosa cell tumour diagnosed as malignant granulosa cell tumour. Under metastatic group of tumours; one case of Krukenberg tumour comprising of 1.67% of all ovarian tumours. Patient had bilateral solid ovarian tumours (Table-7).

Table 1: Distribution of Ovarian Tumour and Tumour like Lesions

Total No of cases		Tumour		Tumour like lesions	
No.	%age	No.	%age	No.	%age
150	100	60	40	90	60

Table 2: Show Mode of Presentation of Non Neoplastic Lesions

Non neoplastic lesions	Abdominal pain		Menstrual irregularities		Pain with menorrhagia		Total	
	No.	%age	No.	%age	No.	%age	No.	%age
Follicular cyst	-	-	30	100	-	-	30	100
Corpus luteal cyst	30	62.5	12	25	6	12.5	48	100
Endometriosis	12	100	-	-	-	-	12	100
Total	42	33.33	42	53.33	6	13.33	90	100

Table 3: Show Age-Wise Distribution of Non Neoplastic, Tumour like Ovarian Lesions

Age Group (in years)	No. of cases	%age
<19	6	6.67
20-39	54	60
40-59	30	33.23
>60	-	-
Total	90	100

Table 4: Distribution of Benign, Borderline and Malignant Ovarian Neoplasms

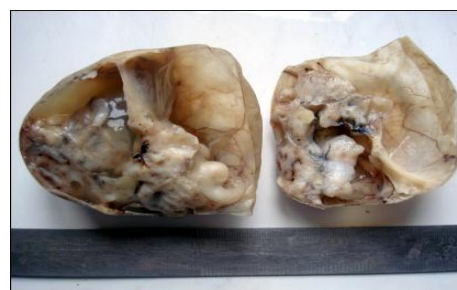Total No of cases		Benign		Borderline		Malignant	
No.	%age	No.	%age	No.	%age	No.	%age
60	100	45	75	1	1.66	14	23.34

Table-5: Show Mode of Presentation of Neoplastic Lesions

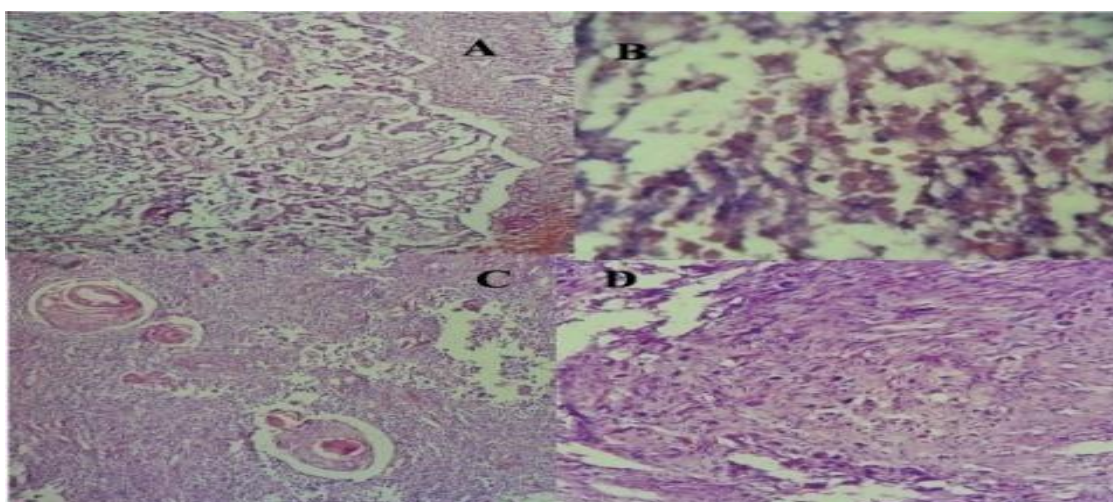
Clinical Features	No. of cases	%age
Abdominal mass	41	69.33
Abdominal pain	20	33.33
Post menopausal bleeding	8	13.33
Abnormal bleeding P/V (Premenopausal)	5	8.33
Ascites	2	3.33
Low backache	1	1.67



Gross specimen of piecemeal graywhite tissue of malignant mixed germ cell tumour



Gross specimen of mature cystic teratoma showing grayish white solid areas with cystic areas



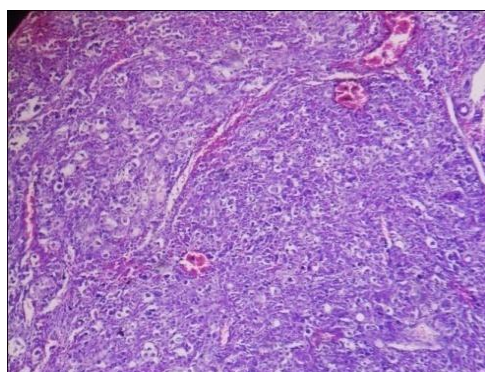
Photomicrographs of malignant mixed germ cell tumour showing (A) Embryonal carcinoma (100x, H&E), (B) Yolk sac tumour showing hyaline globules (400x, H&E), (C) Mature Teratoma showing keratinised stratified squamous epithelium (100x, H&E), and (D) Immature teratoma (400x, H&E),

Table 6: Show Histological Types of Neoplastic Lesions

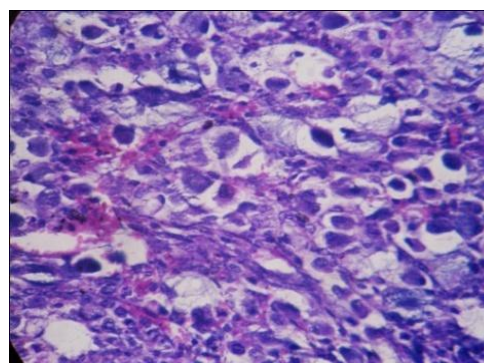
Group	Total		Benign		Borderline		Malignant	
	No	%age	No	%age	No	%age	No	%age
Surface Epithelial Tumours	43	71.67	35	77.77	1	100	7	50
Sex cord stromal tumours	2	3.33	-	-	-	-	2	14.28
Germ cell Tumours	14	23.33	10	22.23	-	-	4	28.58
Secondary (Metastatic) Tumours	1	1.67	-	-	-	-	1	7.14
Total	60	100	45	100	1	100	14	100

Table 7: Show Detailed Morphological Analysis of Ovarian Neoplasms

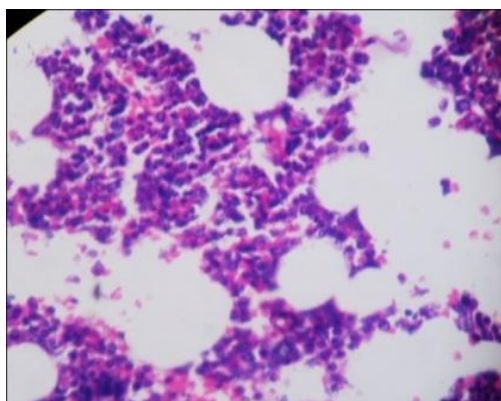
Morphological types	No.	% age	Age (in yrs)	Size (in cms)			Consistency			Laterality	
				<10	11-20	21-30	Cystic	Solid	Mixed	U/I	B/I
1. Surface epithelial tumours	43	71.66									
A) Serous tumours	23	38.33									
a) Benign	19	31.66	11-75	15	4	-	18	-	1	18	1
b) Borderline (APST)	1	1.67	65	-	1	-	-	-	1	1	-
c) Malignant	3	5	46-52	-	3	-	2	-	1	1	2
B) Mucinous Tumours	18	30									
a) Benign	16	26.67	22-45	13	3	-	15	-	1	15	1
b) Malignant	2	3.33	45-46	1	-	1	-	-	2	1	1
C. Endometrioid Carcinoma	1	1.67	55	-	1	-	-	1	-	1	-
D. Undifferentiated	1	1.66	18	-	1	-	-	1	-	1	-
2. Sex Cord Stromal Tumours	2	3.34									
a) Granulosa Cell Tumours	1	1.67	75	-	1	-	-	-	1	1	-
b) Fibrothecoma	1	1.67	48	-	1	-	-	1	-	1	-
3. Germ Cell tumours	14	23.33									
A. Teratoma	11	18.34									
a) Immature	1	1.67	32	1	-	-	-	-	1	1	-
b) Mature	9										
1) Benign cystic teratoma	9	15	15-62	9	-	-	9	-	-	9	-
c) Struma ovarii	1	1.67	28	1	-	-	-	-	1	1	-
B. Dysgerminoma	1	1.67	40	-	1	-	-	1	-	1	-
C. Endodermal sinus tumour	1	1.67	34	-	1	-	-	-	1	1	-
E. Mixed Germ Cell Tumours	1	1.67	23	-	-	1	-	-	1	1	-
4. Metastatic Non-Ovarian Tumour	1	1.67									
A. Krukenberg Tumour	1	1.67	36	-	1	-	-	-	1	-	1
Total	60	100		39	19	1	44	4	12	53	6



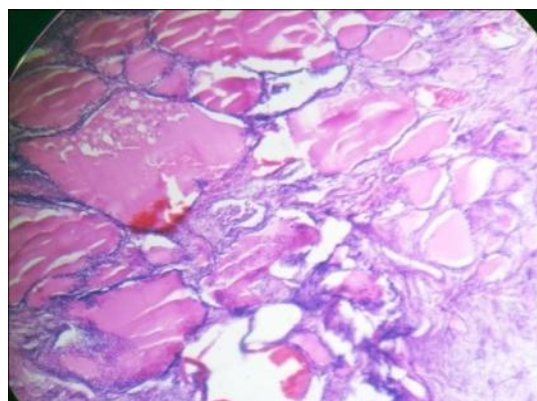
Photomicrograph of dysgerminoma (100x, H&E) showing tumor cells separated by fibrous septae infiltrated by lymphocytes.



Photomicrograph of krukenberg tumour (400x, H&E) showing signet ring cells filled with mucin.



Photomicrograph of teratoma of ovary showing hematopoietic tissue(400x, H&E)



Photomicrograph of teratoma of ovary showing thyroid tissue (400x, H&E) .

DISCUSSION

According to this study 75% were benign, 1.66% borderline and 23.34% malignant. This is in concordance with the study of Couto et al^[10] and Maheshwari et al^[11].

Present study is in concordance with Pilli et al^[12] and Ramachandra et al^[13] where incidence of ovarian neoplastic lesions was more common in 21-40 years of age group. Kar et al^[14] reported high incidence of ovarian tumours in 41-60 years age group.

In the present study, the majority of benign tumours occurred in the age group of 21-40 years. This finding is consistent with the studies by Randhawa^[15] and Ramachandra et al^[13]

In the present study 54% were unilateral and 10% were bilateral. This is in concordance with the study of Couto et al^[10]

Present study is concordant with studies by Gupta et al^[16] and Misra et al^[17] and with Couto et al^[10] which showed high incidence of malignant tumour having more number of tumours with solid and mixed consistency.

Majority of the benign lesions (86%) in the present study were cystic in consistency. And majority of malignant lesions (57.14%) were having mixed consistency. This result is concordant with studies by Gupta et al^[16] and Misra et al^[17].

According to the present study the most common symptom with which the patients presented was abdominal mass followed by abdominal pain. This is in concordance with the study of Couto et al^[10] and Maheshwari et al^[11].

Among the individual tumours, the commonest benign epithelial tumours were serous cystadenoma (31.66%), followed by mucinous cystadenoma (26.67%). Among malignant epithelial tumours, serous cystadenocarcinoma (5%) was the most common, and followed by Mucinous cystadenocarcinoma. Similar findings were seen in studies by Maheshwari et al^[11] and Gupta et al^[12].

This study accounted for 19 cases (31.66%) of serous cystadenoma which is low in incidence as compared to studies by Misra et al^[17] and Maheshwari et al^[11] which reported a higher incidence of serous cystadenoma, that is, 49% and 46.01%, respectively.

Peak age of occurrence of serous cystadenocarcinoma were seen in 5th to 6th decade of life in present study, a finding similar to that of Pilli et al^[12].

Mucinous cystadenoma accounted for 16 cases (26.67%) out of 60 cases of neoplastic lesions. Similar findings have been reported by Prabhakar et al^[18] (18%) and Maheshwari et al^[11] (13 %).

Two cases of mucinous cystadenocarcinoma were reported in present study. The other authors like Maheshwari et al^[11], Pilli et al^[12] and Prabhakar et al^[18] showed an incidence of 0.25 %, 4%, and 5% respectively.

There was 1 case of Endometrioid carcinoma (1.67%), similar incidence was seen in studies by Prabhakar et al^[18] (1.1%). Studies by Maheshwari et al^[11] and Dawar^[19] showed higher incidence (3.65% and 5.7% respectively).

There was one case of granulosa cell tumour accounting 1.67% of total neoplastic lesions. Incidence was slightly less compared to the study done by Ramachandra et al^[13] with granulosa cell tumour accounting for 2.7%.

Mature cystic teratoma, most common germ cell tumour, accounted 15% of total neoplastic lesions and 64.29% among germ cell tumours.

Studies by Tyagi et al^[20], Gupta et al^[16] and Couto et al^[10] which showed an incidence of 18.46%, 23.13 % and 15.45% respectively among total neoplastic tumours.

There was one case (1.67%) of malignant mixed germ cell tumour with a rare combination of yolk sac tumour and immature teratoma. Studies by Prabhakar et al^[18] and Gupta et al^[16] showed incidence of 0.78% and 0.59% of malignant mixed germ cell tumours in their studies.

One case of Krukenberg tumour was detected in a female aged 36 years, accounting 1.67% of total neoplastic lesions. Tumour was confined to both the ovaries. Studies by Misra RK et al^[17], Prabhakar et al^[18], Couto et al^[10] showed an incidence of 1.07%, 1.57% and 1.46% respectively which is concordant with present study.

CONCLUSION

Effective therapeutic management of ovarian malignant tumours continues to be a challenge to the oncologist. An accurate histopathological diagnosis combined with clinical staging will help in rendering prompt and appropriate treatment to the patient.

REFERENCES

1. Rosai J. Female reproductive system. In : Rosai and Ackerman's Surgical Pathology. St. Louis Mosby 2004; 9(2):1649-1736.
2. Kumar V, Abbas AK, Fausto N, Aster JC. The Female genital tract. In : Robbins and Cotran Pathologic basis of disease. Christopher Crum eds. Philadelphia: Elsevier; 2010; 8:1005-64.
3. Scully RE: World Health Organization International Histological Classification of tumors. New York: Springer; 1999.
4. Seidman JD and Kurman RJ. Subclassification of serous borderline tumors of the ovary into benign and malignant types. Am J Surg Pathol. 1996; 20(11):1331-45.
5. Rock JA and Jones HW III. Ovarian cancer: etiology, screening and surgery. In: Te Linde's Operative Gynaecology. Van Nagel JR, Gershenson DM eds. Philadelphia: Lippincott Williams and Wilkins; 2009;10(49):1307-39.
6. Novak and Woodruff. Ovarian Neoplasia : Mesothelial; Stromoepithelial Lesions – Primarily Epithelial (Benign, of low malignant potential) and malignant (serous, mucinous, endometrioid, mesonephroid, mesothelial) . In : Novak's Gynaecologic and Obstetric Pathology with clinical and endocrine relations. International Edition W.B. Saunders Co. 1979; 21:396-436.
7. Berek JS. Ovarian and fallopian tube cancer. In: Berek and Novak's Gynaecology. Philadelphia: Lippincott Williams and Wilkins; 2007; 14:1457-58.
8. Kumar P and Malhotra N. Tumors of Ovary. In: Jeffcoate's principles of gynaecology. International edition. Arnold Jaypee Brothers 2001; 7(33):524-60.
9. Kumar RJ. Non-specific tumours of the ovary, including mesenchymal tumours and malignancy lymphomas. In: Blaustein's pathology of female genital tract. Blaustein A and Kurman RJ Ed. New York: Springer-Verlag; 2002; 5:1035-62.
10. Couto F, Nadkarni NS, Rebello MJ. Ovarian tumors in Goa: A clinicopathological study. J Obstet Gynecol India. 1993; 43:408-12.
11. Maheshwari V, Tyagi SP, Saxena K et al: Surface epithelial tumors of the ovary. Indian J Pathol Microbiol. 1994; 37(1):75-85.
12. Pilli GS, Suneeta KP, Dhaded AV, Yenni VV. Ovarian tumors. A study of 282 cases. J Indian Med Assoc. 2002; 100(7):420,423-4,447.
13. Ramachandra G, Harilal KR, Chinnamma K, Thangavelu H. Ovarian neoplasms - A study of 903 cases. J Obstet Gynecol India. 1972; 22:309-315.
14. Kar Tushar, Kar Asanranthi Mohapatra PC. Intraoperative cytology of ovarian tumours. J Obstet Gynecol India. 2005; 55(4):345-349.
15. Randhawa I and Lata P. A study of ovarian neoplasm. J. Obstet. Gynec. India 1980;30:531-535.
16. Gupta SC, Singh PA, Mehrotra TN, Agarwal R. A clinico-pathological study of ovarian tumours. Indian J Pathol Microbiol. 1986;29(4):354-62.

17. Misra RK, Sharma SP, Gupta U, Gaur R, Misra SD. Pattern of ovarian neoplasm in eastern U.P. J obstet Gynec India. 1990;41(2):242-246.
18. Prabhakar BR and Maingi K. Ovarian tumours--prevalence in Punjab. Indian J Pathol Microbiol. 1989; 32(4):276-81.
19. Dawar R. Surface epithelial tumors of ovary. Indian J Med Paediatr Oncol. 2004; 25(1):5-8.
20. Tyagi SP, Tyagi GK, Logani KB. A pathological study of 120 cases of ovarian tumours. J Obstet Gynecol India. 1967; 17:423-33.