

Adenomatoid Odontogenic Tumour of the Mandible Arising From a Dentigerous Cyst: A Case Report.

Anita Dnyanoba Munde^{1*}, Ravindra R Karle², Swapna Sachdev¹, and Sunil Sahuji¹.

¹Department of Oral Medicine and Radiology, Rural Dental College, PIMS, Loni, Tal-Rahata, Dist - Ahmednagar, Maharashtra, India.

²Department of Pathology, Rural Medical College, PIMS, Loni, Tal-Rahata, Dist-Ahmednagar, Maharashtra, India.

Research Article

Received: 29/10/2013

Revised: 08/11/2013

Accepted: 15/10/2013

*For Correspondence

Department of Oral Medicine and Radiology, Rural Dental College, PIMS, Loni, Tal-Rahata, Dist-Ahmednagar, Maharashtra, India.

Keywords: adenomatoid odontogenic tumour, canine, dentigerous cyst, mandible

ABSTRACT

Adenomatoid odontogenic tumour (AOT) is an uncommon benign lesion derived from the complex system of dental lamina or its remnants. It is categorized into 3 variants (follicular, extrafollicular and peripheral). It affects young individuals with female predominance, commonly located in anterior maxilla and is usually associated with impacted canine. A 20 year old female presented with a large radiolucent lesion associated with impacted canine in mandibular anterior region which was clinically diagnosed as dentigerous cyst (DC). The microscopic examination revealed the presence of AOT in the fibrous capsule of the DC. This case represents an odontogenic cyst with neoplastic development, containing both epithelial and mesenchymal components. Very few cases of AOT associated with DC have been reported till date.

INTRODUCTION

The Adenomatoid odontogenic tumour (AOT) has been known to the pathologists for the past 100 years as a benign slow growing tumour. It was first described by Ghosh ^[1] in 1934 as an adamantinoma of the maxilla and was first recognized as a distinct pathological entity by Staphne ^[2] in 1948. According to the second edition of the WHO Histopathological Typing of Odontogenic Tumours, AOT is defined as a tumour of odontogenic epithelium with duct like structures and with varying degrees of inductive changes in the connective tissue. The tumour may be partly cystic, and in some cases the solid lesion may be present only as masses in the wall of a large cyst ^[3].

AOT is an uncommon tumour of odontogenic origin, composed of odontogenic epithelium in a variety of histoarchitectural patterns. The lesion is benign (hamartomatous) and noninvasive with slow but progressive growth. It accounts for 2-7% of all odontogenic tumours. The majority of the case (88%) are diagnosed in the 2nd and 3rd decades of life. The incidence is higher in females than males (M:F-1:1.9) and has a predilection for the anterior maxilla. The epithelial lining of the odontogenic cyst may transform into an odontogenic benign neoplasm like ameloblastoma, AOT or malignant tumours like squamous cell carcinoma, mucoepidermoid carcinoma ^[4,5,6]. The aim of this paper is to present a rare case of mandibular AOT that originated in the wall of dentigerous cyst, review the literature and stress that some AOT's can arise as a secondary phenomenon within the pre-existing dentigerous cyst.

CASE REPORT

A 20 year old female reported with the complaint of swelling in the anterior mandible since 6 months. The swelling was insidious in onset and gradually progressed to attain the present size. There was no history of trauma, pain in associated teeth and pus or other discharge from the swelling. The medical, surgical and dental histories were not significant.

Extraoral examination revealed a diffuse, roughly oval swelling in the mandibular symphysis and left parasymphysis region, measuring approximately 4x2 cm. Skin over the swelling was of normal colour and was intact. On palpation, it was slightly tender and hard in consistency. Intraorally there was obliteration of the labial

vestibule and expansion of the labial and lingual cortical plates. The swelling was well defined and it extended from mandibular right lateral incisor to mandibular left second premolar. The overlying mucosa was normal. The consistency was hard except in mandibular left second premolar region, where it was soft. There was evidence of over-retained mandibular left canine and mandibular left permanent canine was clinically missing. (Fig 1)

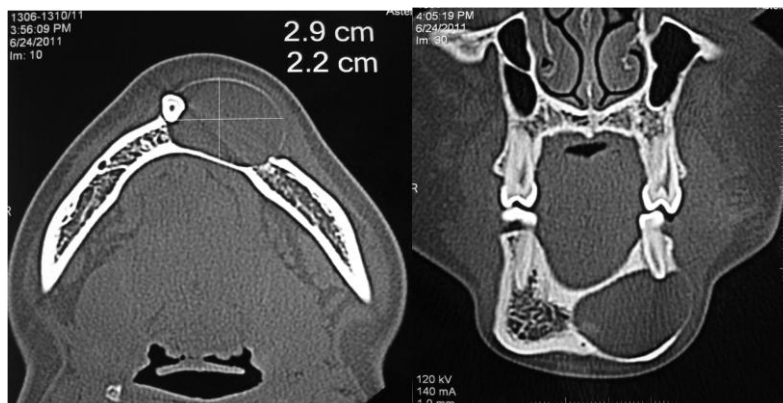


Figure 1

Radiographic and CT examination showed a large unilocular radiolucent lesion, measuring 2.9 x 2.2 cm extending from mandibular right lateral incisor to mandibular left second premolar. The borders of the radiolucency were well defined, smooth and corticated. The mandibular left permanent canine was impacted, and was displaced inferiorly towards right side in mandibular right lateral incisor region. There was thinning and expansion of the labial cortical plate and inferior border of mandible. The lesion resulted into divergence and external root resorption apically with mandibular left central, lateral incisor and first premolar. (Fig 2,3)

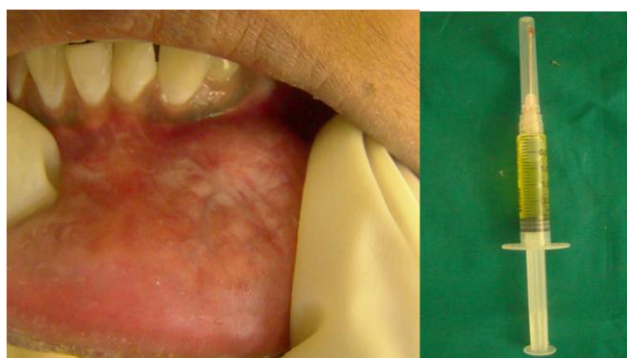


Figure 2

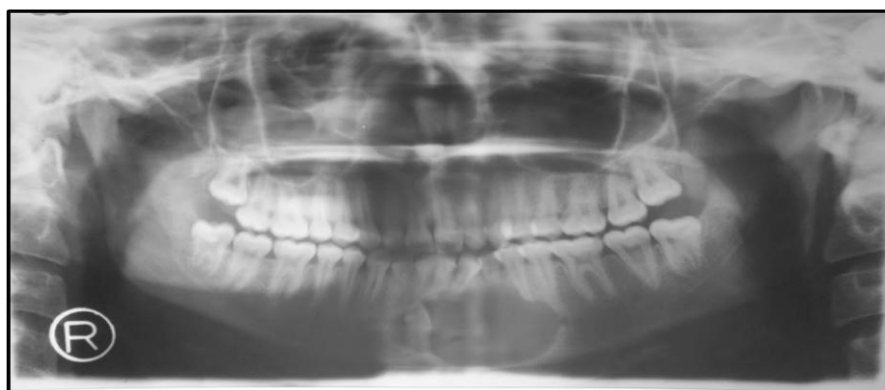

Figure 3

Aspirational biopsy was performed and the product consisted of copious amount of clear yellow fluid of approx. 2.5 ml without any crystals. (Fig 1) Electric pulp vitality test showed delayed response with mandibular central incisors and no response to mandibular left lateral incisor, premolars and deciduous canine. The provisional diagnosis of dentigerous cyst was made. Central giant cell granuloma, adenomatoid odontogenic tumor, unicystic ameloblastoma and odontogenic keratocyst were considered in the differential diagnosis.

The cyst was enucleated along with the impacted lower permanent canine. The cavity was packed with a allograft inside and the flap was sutured in place. Endodontic treatment was performed for mandibular incisors, deciduous canine and left first and second premolar before the surgical enucleation. Healing was uneventful and there were no signs of recurrence a year after the surgery.(Fig 4)

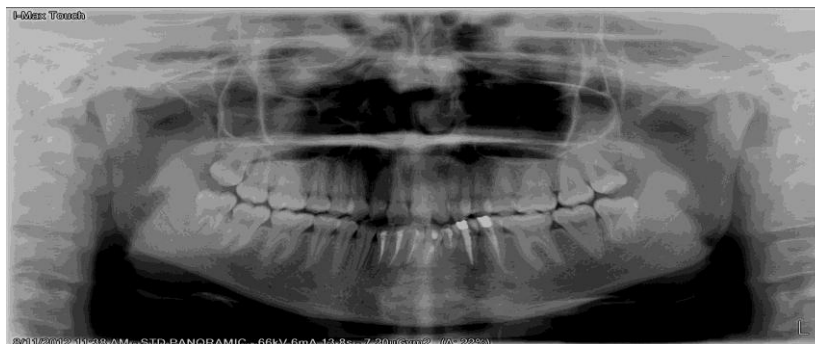

Figure 4

Histopathological examination revealed a cystic cavity lined by thin non-keratinized stratified squamous epithelium and underlying connective tissue capsule. Connective tissue capsule showed presence of encapsulated tumor mass. Tumor mass consisted of odontogenic islands, odontogenic cells arranged in the form of sheets, follicles, ducts and rosette pattern. Odontogenic follicles lined by tall columnar ameloblast like cells and centrally placed stellate reticulum like cells. Histopathological diagnosis was confirmed as Dentigerous cyst with AOT.(Fig 5)

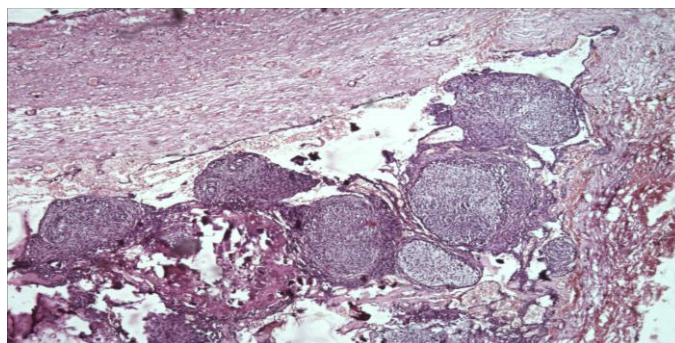


Figure 5

DISCUSSION

AOT is a slow growing lesion, constituting only 3-7% of all odontogenic tumours and 0.1% of tumours of jaws. It has predilection for anterior maxilla, usually associated with impacted canine. It is commonly seen in young females in the second decade of life. In our case, the lesion occurred in the mandible which is unusual. Clinically it presents as an asymptomatic swelling, but may be associated with cortical expansion as in our case. The involved teeth are commonly impacted and adjacent teeth may be slightly displaced. Root resorption is not a usual feature. Radiographically it manifests as an unilocular radiolucency with well defined corticated borders, surrounds an unerupted tooth and sometimes contain faint radiopaque foci of calcifications. In the cases where the lesion has no radiopaque foci, as in our case, a DC is the preferred clinical diagnosis. However, an AOT often appears to envelope the crown as well as root, as seen in our case, unlike the DC which does not envelope the roots [5,6].

Philipsen et al subdivided this condition into three groups referred to as follicular, extrafollicular and peripheral. These variants have common histologic characteristics that indicate a common origin, as derived from the complex system of dental lamina or its remnants [7]. The follicular and extrafollicular variant accounts for 96% of all AOT and 71% of these are follicular variants. The peripheral variant is the rarest with few cases reported so far. The former two variants are intraosseous (central) and more commonly found in the maxilla than in the mandible at a ratio of approx 2:1 [8].

The follicular variant is associated with the crown or often a part of the root of an impacted tooth, most commonly maxillary canine and rarely the permanent molars and deciduous teeth. Therefore, this variant is often initially diagnosed as a dentigerous cyst based on clinical and radiological features. The extrafollicular variant is not associated with the crown of an unerupted tooth. Instead this presents as a well-defined, unilocular radiolucency between, above or superimposed upon the roots of erupted permanent teeth. Consequently, a clinical diagnosis of

a residual, radicular, globulomaxillary or lateral periodontal cyst can be made. The peripheral variant usually appears as a gingival fibroma or epulis in the anterior maxilla (88%) [8,9].

The histogenesis of AOT is controversial with various concepts being proposed as to its origin from fully formed enamel organ, dental lamina and/or its remnants and from odontogenic cysts [9]. Some believe they originate from the odontogenic epithelium of a DC. The hypothesis that follicular AOT's arise from the reduced enamel epithelium (REE) that lines the follicles of unerupted teeth is fairly conclusive and is supported by evidence both morphological and immunocytochemical in nature. They surround the crown and are attached to the necks of unerupted teeth in a true follicular relationship. Many present as cystic lesions with only mural nodules of AOT lesional tissue and in some instances origin of the lesional tissue from the REE can be demonstrated histologically.

Whether origin of the follicular variant occurs before or after cystic expansion has taken place is open to conjecture. If it occurs after cystic expansion then this effectively means origin from a dentigerous cyst and several such cases have been published [4,9]. If it occurs before cystic expansion then the tumour tissue will fill the follicular space and AOT will present as solid tumour.

In the present case, AOT and Dentigerous cyst are found in the same lesion. Clinical, radiographic and microscopic findings are consistent with the descriptions of the lesion in the dental literature. As previously mentioned AOT's are usually solid but are occasionally cystic. Very few cases have been reported that arise in association with dentigerous cyst. Santos et al [10] reported a case of AOT being developed in the fibrous capsule of the DC. Garcia pola et al [4] described the proliferation of an AOT in the epithelial border of a DC. Nonaka reported a case of AOT associated with a DC.

A systematic search of the English language medical literature revealed only 12 such cases and only 3 of them occurred in the mandible. The clinical characteristics of these 12 cases and the current case are summarized in the Table-1.

Table 1: Reported cases of Adenomatoid odontogenic tumour arising from a dentigerous cyst

Author	Age	Sex	Site	Associated tooth	Radiographic features	Associated Cyst
Santos et al. Non -English literature	NA	NA	NA	NA	NA	Dentigerous cyst
Valderrama (1988)	16	F	Maxilla	24	ycneculoidar ralucolinU	Dentigerous cyst
Warter et al (1990)	8	M	Mandible	43, 44	Unilocular radiolucency	Dentigerous cyst
Tajima et al (1992)	15	M	Maxilla	28	A well defined radiopaque mass & crown of unerupted 28	Dentigerous cyst
Garcia-Pola et al (1998)	12	M	Maxilla	23	Unilocular radiolucent lesion surrounding the crown of 23 extending towards the root	Dentigerous cyst
Bravo et al (2005)	14	M	Maxilla	13	Expansile radiolucent lesion with impacted maxillary canine.	Not categorized
Nonaka et al (2007)	13	F	Maxilla	23, 24	Unilocular radiolucency with few radiopaque foci, associated with canine & premolars.	Dentigerous cyst
YK Chen (2007)	15	M	Maxilla	23	Unilocular radiolucency .	Dentigerous cyst
Baby John (2010)	39	F	Maxilla	27	Unilocular radiolucency	Dentigerous cyst
Simarpreet Sandhu (2010)	25	F	Maxilla	13	Unilocular radiolucency	Dentigerous cyst
Zama Moosvi (2011)	13	F	Mandible	32	Unilocular radiolucency .	Dentigerous cyst
Komal Khot (2011)	17	F	Mandible	43	Unilocular radiolucency	Dentigerous cyst
Current case (2012)	20	F	Mandible	33	Unilocular radiolucency	Dentigerous cyst

AOT and DC are both benign, encapsulated lesions and conservative surgical enucleation or curettage is the treatment of choice. The prognosis for a dentigerous cyst is good and recurrences are very rare after complete removal of the lesion. There have been some rare reports of aggressive behavior on the part of AOT.

Our present case of an AOT arising from a dentigerous cyst is a rare entity. Further AOT itself is not common in the mandible. Hence this case highlights the neoplastic potential of odontogenic cysts and alerts us for a meticulous histopathological evaluation of the biopsied specimens which can unfold the mystery behind origin of tumours.

REFERENCES

1. Ghosh LS. Adamantinoma of the upper jaw: Report of a case. Am J Pathol. 1934;10:773-90.
2. Stafne EC. Epithelial tumours associated with developmental cysts of the maxilla: A report of three cases. Oral Surg Oral Med Oral Pathol. 1948;1:887-943.

3. Kramer IRH, Pindborg JJ, Shear M. WHO International Histological Classification of tumors. Histological typing of odontogenic tumors, 2nd ed. Berlin:Springer Verlag;1992.
4. Garcia-Pola VM, Gonzalez Garcia M, Lopez-Arranz JS, Herrero Zapatero A. Adenomatoid odontogenic tumour arising in a dental cyst:Report of unusual case. J Clin Pediatr Dent. 1998;23:55-8.
5. McMillan MD, Smillie AC. Ameloblastomas associated with dentigerous cysts. Oral Surg Oral Med Oral Pathol. 1981;51:489-96.
6. Jivan V, Altini M, Meer S, Mohamed F. Adenomatoid Odontogenic tumour (AOT) originating in a unicystic ameloblastoma:A case report. Head and Neck Pathol. 2007;1:146-49.
7. Philipsen HP, Reichart PA, Zhang KH. Adenomatoid odontogenic tumour:Biologic profile of 499 cases. J Oral Pathol and Med. 1991;20:149-58.
8. Philipsen HP, Reichart PA. Adenomatoid odontogenic tumour:Facts and figures. Oral Oncol. 1999;35:125-31.
9. Tajima Y, Sakamoto E, Yamamoto Y. Odontogenic cyst giving rise to an adenomatoid odontogenic tumour:Report of a case with peculiar features. J. Oral Maxillofac Surg. 1992;50:190-3.
10. Santos TCRB et al. Tumor odontogenico adenomatoide associado a cisto dentigero. Relato de um casoe revisao da literatura. RBO. 1986;XLIII:8-14.