

Combined Spinal-Epidural Anesthesia for an Elective Cesarean Section in a Marfan Patient with a History of Bentall Operation Who Developed an Acute Extensive Aortic Dissection: A Case Report

Mohammed Abdelsalam Menshawi*, Islam Mohammed Shehata, Bahaa El-din Hassan Ewees

Faculty of Medicine, Ain Shams University, Cairo, Egypt

Case Report

Received date: 22/03/2019

Accepted date: 09/04/2019

Published date: 16/04/2019

*For Correspondence

Mohammed Abdelsalam Menshawi, Faculty of Medicine, Ain Shams University, Cairo, Egypt.

Tel: 01112095802

E-mail: mmenshawi80@outlook.com

Keywords: Aortic dissection, Bentall, Pregnancy, Regional anesthesia

ABSTRACT

Aortic dissection during pregnancy is a critical event for both the mom and the fetus. We present a case report of combined spinal-epidural anesthesia for aortic dissection (Stanford type B) in a parturient woman with Marfan syndrome at her 37th week of gestation and had a history of Bentall procedure 3 years ago. There is no standard consensus about pregnancy and aortic dissection, so our case is an original one which can enrich the anesthesia management in this uncommon situation.

BACKGROUND

Marfan syndrome is an autosomal dominant inherited connective tissue disease which affects many organs, but 90 % of mortality attributed to Marfan syndrome is related to the cardiovascular complications such as aortic dilation and dissection ^[1].

Aortic dissection during pregnancy is a life-threatening uncommon condition with a survival rate of only 20%-30% ^[2]. About 50% of the aortic dissections during pregnancy are attributed to Marfan syndrome with a common incidence at the third trimester due to the hyperdynamic state and the hormonal effects on the vascular tree at that period ^[3].

Combined spinal-epidural anesthesia has the benefits of intraoperative hemodynamic stability and an excellent postoperative pain control via epidural catheter with lower failure rate ^[4].

CASE REPORT

A 35 year old lady with Marfan syndrome was admitted at her 37th week gestational age. She had the pathognomic body habitus of Marfan syndrome (Tall, thin with steinberg sign (**Figure 1**)). After the previous pregnancy (the third one) at 32 years of age, she suffered from unexplained dyspnea and chest pain and was diagnosed as ascending aortic dissecting aneurysm for which she underwent a Bentall operation. After operation, she was maintained on antihypertensive drugs which she did not take regularly and oral anticoagulant therapy which was shifted to heparin during this pregnancy that was incidentally discovered by missing her period because she did not take any contraceptive drugs.

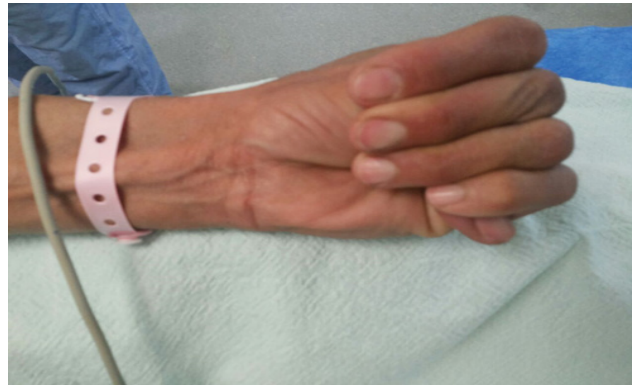

Figure 1. Tall, thin with steinberg sign.

At the fourth day of the 36th week of gestation, she suffered from chest pain referred to the back, so her treating physician performed CT with contrast for chest, abdomen and pelvis which showed dissecting flap extending from the ascending aorta involving the arch, descending aorta in the chest and the abdomen till the bifurcation with false and true lumen, but the aortic branches arising from the true lumen with average perfusion for different organs (**Figure 2**).

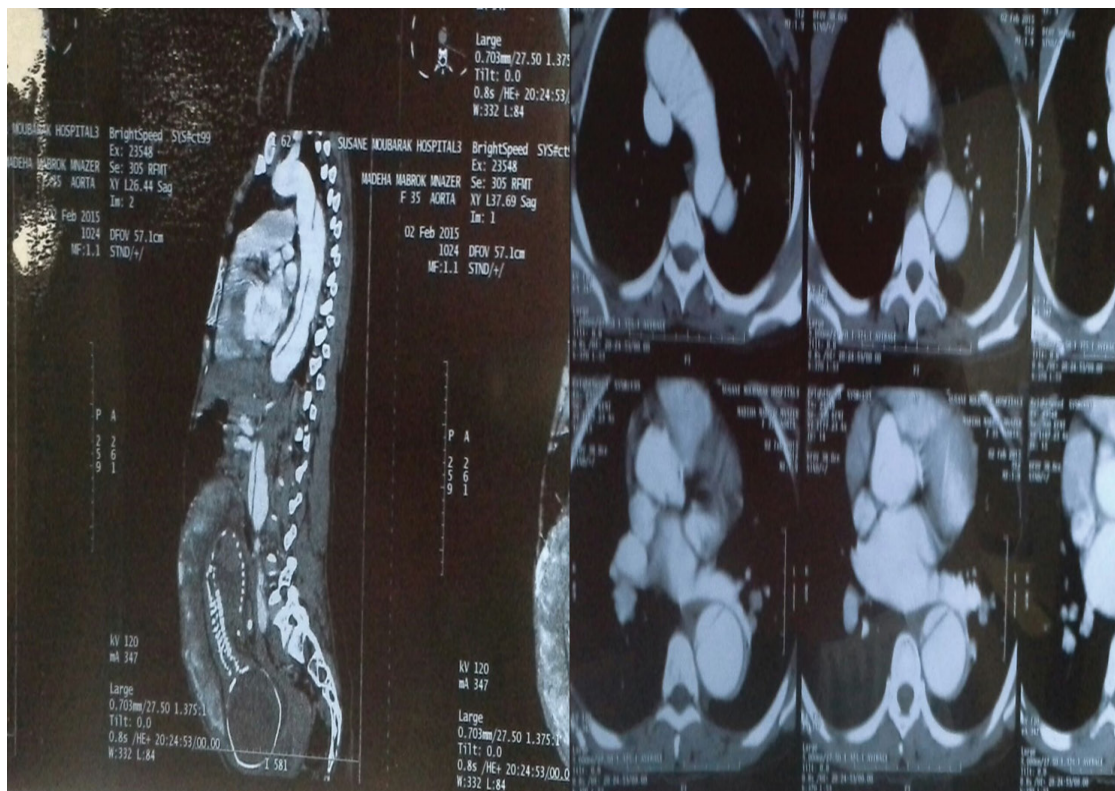


Figure 2. Aortic branches arising from the true lumen.

She was transferred to our tertiary hospital where the medical consensus of Senior anesthesiologist, cardiothoracic surgeon, vascular surgeon, cardiologist and obstetrician have made the decision of immediate cesarean section followed by transfer to the cardiovascular academy for management of the aortic dissection.

On admission, metallic click of the prosthetic aortic valve was auscultated with a stethoscope. Her initial vital signs and laboratory tests of complete blood count, coagulation profile, hepatic virology and kidney and liver functions were within normal. The transthoracic echocardiography showed a left ventricle ejection fraction of 60%, a well-functioning prosthetic aortic valve (Peak Gradient/Mean Gradient=44/22 mmHg), dilated left atrium and severe tricuspid regurg with right ventricular systolic pressure of 20 mmHg. Prenatal ultrasound showed single viable fetus and the obstetrician started dexamethasone injection and heparin was stopped before the day of surgery.

The patient we referred to the operative room where an 18G intravenous cannula was inserted; electrocardiogram leads and pulse oximeter were attached for continuous monitoring and with aseptic precautions left right radial arterial cannula and right internal jugular venous central venous were placed for invasive monitoring.

The baseline vital data were heart rate: 67 beats/min, blood pressure: 110/76 mmHg and SpO₂ 98% on oxygen by facemask.

Ampicillin/Sulbactam and gentamicin were administered for prophylaxis against bacterial endocarditis. Preloading was done with 500 ml of lactated Ringer solution then in sitting position; An 18-gauge Tuohy needle was placed at the interspace between L3-4 under aseptic conditions using a midline approach with the loss-of air resistance technique (no backflow of CSF or blood was evident) then epidural catheter was placed via the Tuohy needle and fixed at 9 cm.

Spinal anesthesia was then performed through needle technique employing a 25 G Quincke spinal needle and 2 ml of 5% hyperbaric bupivacaine (10 mg) and around 25 Mcg fentanyl (total volume 2.5 ml) was administered. Patient was then positioned supine with a 15 degree left lateral tilt and oxygen mask was applied so that sensory block at T10 segment was achieved then we injected 6 ml of isobaric bupivacaine 0.5% (30 mg) 2 ml every 5 min at the epidural space till Sensory block up to T4 segment was achieved gradually after 15 minutes. We prepared Noradrenaline infusion to avoid the tachycardia of Ephedrine and because phenylephrine was not available at our country.

Sub umbilical midline incision was performed by the obstetrician (for good hemostasis as they explained) and a 2 kg female baby was delivered and admitted at the neonatal care unit. Uterine tonicity was augmented by oxytocin slow infusion only 20 I.U. diluted over 500 ml of normal saline (we avoided using the Methergine because of its side effects as hypertension which may increase the shearing forces at the weak point of the aortic tree). Tubal ligation was performed after informed consent and the duration of the surgery was 60 min.

Oxygen saturation was maintained intraoperative between 97%-99%, heart rate between 70-80/min and blood pressure was maintained between systolic (105-120 mmHg) and diastolic (55-75 mmHg) with urine output of 1 ml/kg/hr intraoperatively, so hemodynamics data were stable and we did not need to give any vasopressors.

We transferred the patient to intensive care unit with blood pressure 125/75 mmHg, heart rate 80 bpm and oxygen saturation 98%. Postoperative analgesia was continued with 8 ml per hour of 0.125% isobaric bupivacaine through epidural catheter which was titrated to maintain pain score 3-4/10. On the second post-operative day she was hemodynamically stable and was shifted to the ward without any cardiovascular complications on enoxaparin and beta blocker as antihypertensive drugs. Two days later, the patient left the hospital against the medical advice and refused to be transferred to the cardiovascular academy as was planned.

DISCUSSION AND CONCLUSION

The incidence of aortic aneurysms in patients with Marfan syndrome increased at the third trimester because of increase in cardiac output (due to the increase in both of heart rate and stroke volume) which can cause an intimal injury of the aorta ^[5]. Also the enlarged uterus which compresses the aorta, causing an increase in the vessel outflow resistance, so increase the risk of dissection. Adding to these factors the high blood pressure and our patient did not regularly take her medications which can aggravate the risk of dissection.

If aortic dissection developed before 30 weeks of gestation, so an immediate aortic repair surgery is recommended. However, if it developed after 30 weeks of gestation, cesarean section has to be performed cautiously just before heart surgery ^[6]. So that in our case, where aortic dissection occurred at the 37th week of gestation dissection, cesarean section was recommended and here was the dilemma, regional or general anesthesia? We preferred the combined spinal epidural anesthesia (CSEA) for many advantages of it and for many disadvantages of general anesthesia in this difficult case.

As regard the CSEA, has been used effectively to provide anesthesia for cesarean section with a lower failure rate with better intraoperative patient satisfaction and postoperative excellent analgesia which of most important in our case because the stress response of the postoperative pain that may increase the aortic dissection ^[7].

The spinal component provides a fast onset of a solid block and the placed epidural catheter provides steady continuous analgesia as happened in our case ^[8]. We inject only 2.5 ml intrathecally (not too much volume at this tall patient) and augment the level by another injection through the epidural catheter while waiting to block the surgical level required for cesarean section and this avoid the rapid decrease in systemic vascular resistance, reflex tachycardia and the higher need for vasopressors associated with single shot spinal technique as solo technique which can be hazardous for the aortic dissection. Moreover, many cases of failed single shot spinal anesthesia in Marfan patients were reported maybe due to dural ectasia which is a ballooning of the dural sac with greater cerebrospinal fluid volume than normal in the lumbar theca and accused to restrict the extension of intrathecally injected local anesthetic ^[9].

As regard the general anesthesia, the stress response associated during tracheal intubation may increase the aortic dissection, especially that both pregnancy and Marfan syndrome (high arched palate with crowded teeth may make visualization of the larynx difficult) are factors of difficult intubation ^[10]. Moreover, the adverse effects of positive-pressure ventilation especially at marfan patients with increased risk of pneumothorax and the increasing the risk of aspiration of gastric contents due to delayed gastric emptying associating pregnancy.

In our case report, we reported a successful combined spinal epidural anesthesia without any cardiovascular nor neurologic

complications for elective cesarean section in a pregnant patient with Marfan syndrome who underwent Bentall operation 3 years ago and complicated at the present pregnancy with acute aortic dissection (Stanford B) which can provide instructive significance for anesthesia management in this rare condition.

REFERENCES

1. Elkayam U, et al. Cardiovascular problems in pregnant women with the Marfan syndrome. *Ann Intern Med* 1995;123:117-122.
2. Yuan SM. Aortic dissection during pregnancy: A difficult clinical scenario. *Clin Cardiol* 2013;36:576-584.
3. Nasiell J, et al. Aortic dissection in pregnancy: A life-threatening disease and a diagnosis of worth considering. *Acta Obstet Gynecol Scand* 2009;88:1167-1170.
4. Pacini D, et al. Aortic root replacement with composite valve graft. *Ann Thorac Surg* 2003;76:90-98.
5. Vranes M, et al. Pregnancy-related aortic aneurysm and dissection in patients with Marfan's syndrome: Medical and surgical management during pregnancy and after delivery. *Medicina* 2011;47:604-606.
6. Aziz F, et al. Peripartum acute aortic dissection: a case report & review of literature. *J Thorac Dis* 2011;3:65-67.
7. Fan SZ, et al. Low dose of intrathecal hyperbaric bupivacaine combined with epidural lignocaine for caesarean section: A balance block technique. *Anaesth Analg* 1994;78:474-477.
8. Buser R, et al. Combined spinal epidural analgesia for labour in a patient with Marfan's syndrome. *Int J Obstet Anesth* 2007;16:274-276.
9. Lacassie HJ, et al. Dural ectasia: A likely cause of inadequate spinal anesthesia in two parturient with Marfan's syndrome. *Br J Anaesth* 2005;94:500-504.
10. Daftari S, et al. Anesthesia and Marfan's syndrome. *Indian J Anaesth* 2003;47:222-224.