

Intestinal Herniation into the Right Ventral Abdomen in a Broiler

Jyothi Priya R* and Poorani K

College of Poultry Production and Management, TANUVAS, Hosur, India

Case Report

Received date: 09/04/2018

Accepted date: 16/04/2018

Published date: 19/04/2018

*For Correspondence

R. Jyothi Priya, College of Poultry Production and Management, TANUVAS, Hosur, India.

E-mail: drjpriya@rediffmail.com

Keywords: Broiler, Hernia, Intestine, Inflammation, Hemorrhage

ABSTRACT

Abdominal hernias in birds are often not clearly described. A 5-week-old female broiler was presented with a history of abdominal swelling for 3 days followed by sudden death. Herniation in avian species is very rare. Necropsy examination revealed a 5-6 cm sphere-shaped swelling on the right ventral abdomen. On incision of skin, a hernial sac (lined by peritoneal covering) comprising intestinal tract starting from duodenum till caecum was found protruding through an abnormal foramen (about 1-2 cm) of the abdominal muscle into the subcutaneous region of abdominal cavity. Mild congestion of intestinal serosa and mucosal haemorrhages (multifocal) were observed in the hernial sac. The part of pancreas involved in hernia showed multifocal hemorrhage. A cystic dilatation of the mesentery of size 1-2 cm with transparent serous fluid was observed. In the abdominal cavity, intestinal parts (colon and rectum), spleen, kidney and reproductive tract showed mild congestion. Histopathologically, intestinal mucosa revealed moderate hemorrhage, along with inflammation by heterophils, lymphocytes and macrophages. Mesenteric fat and Pancreas also revealed mild degree of congestion and haemorrhage. A focal area of liver showed hypertrophied hepatocytes with narrowed sinusoidal space and mild inflammatory infiltrates by heterophils. Feeding of high energy diets to broilers lead to obesity and also serve as a drive for weakness of abdominal muscles by infiltration of fat which would cause gradual stretching of the abdominal musculature, leading to hernia. This case was diagnosed as Intestinal Herniation into the right ventral abdomen in a 5-week-old female broiler.

INTRODUCTION

Abdominal hernia in birds can be either congenital or acquired and their etiology in birds is unknown. However, abdominal hernia is characterized by separation of aponeurosis of abdominal muscles at ventral midline^[1]. An internal hernia is very rare and is a displacement of the intestine through normal or pathological foramina within the abdominal cavity without formation of a hernia sac. External abdominal hernia is frequently observed in birds, although it is not a true hernia because there is no opening in the aponeurosis of the abdominal muscles and no typical hernia ring. Therefore, entrapment and strangulation of abdominal viscera do not occur^[2].

CASE REPORT

In our study, a 5-week-old female broiler was presented with a history of abdominal swelling for 3 days followed by sudden death. Necropsy examination revealed a 5-6 cm sphere-shaped swelling on the right ventral abdomen. On incision of skin, a hernial sac (lined by peritoneal covering) comprising intestinal tract starting from duodenum till caecum was found protruding through an abnormal foramen (about 1-2 cm) of the abdominal muscle into the subcutaneous region of abdominal cavity (**Figure 1**), glued with adhesions in the form of fibrin mesh. Mild congestion of intestinal serosa and mucosal haemorrhages (multifocal) were observed in the hernial sac. The part of pancreas involved in hernia showed multifocal hemorrhage. A cystic dilatation of the mesentery of size 1-2 cm with transparent serous fluid was observed. In the abdominal cavity, intestinal parts (colon and rectum), spleen, kidney and reproductive tract showed mild congestion.

The representative tissue samples were fixed in 10% neutral buffered formalin; processed by paraffin embedding technique and 4-5 µm thick sections were stained with hematoxylin and eosin^[3].

Histopathologically, intestinal mucosa - duodenum (**Figure 2**), jejunum (**Figure 3**), ileum and caecum (herniated mass)



Figure 1. Ventral abdominal hernia lined by peritoneal cavity.

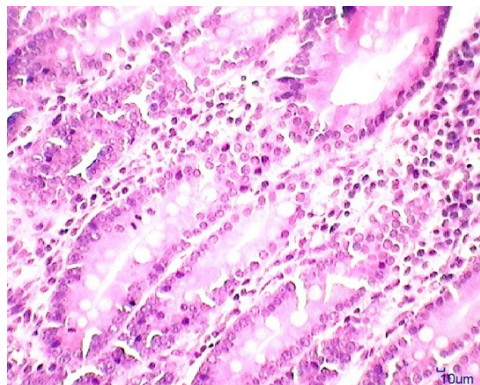


Figure 2. Duodenum (inside herniated mass) showing sub-mucosal congestion with mono-nuclear cell infiltration. H&E x 100.

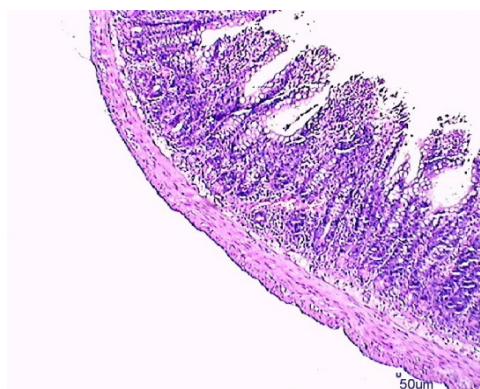


Figure 3. Jejunum (inside herniated mass) showing sub-mucosal congestion with mono-nuclear cell infiltration. H&E x 40.

revealed moderate hemorrhage, along with inflammation by mono-nuclear cell infiltration. Mesentric fat and pancreas (**Figure 4**) also revealed mild degree of congestion and haemorrhage.

In the abdominal cavity, histopathologically a focal area of liver showed hypertrophied hepatocytes surrounded with narrowed sinusoidal space and mild inflammatory infiltrates. Kidneys revealed glomerular degeneration along with mild mono-nuclear cell infiltration. However, histopathology of spleen appeared normal.

The herniated mass gave the bird a pot-bellied appearance with protruding mass visible directly beneath the skin. It may be related to hormonal influences, trauma, stress or other space occupying coelomic masses. Furthermore, there was no sign or indication of thinning or weakness of the abdominal muscles to contribute to the hernial protrusion. The present hernia seems to have been caused by acquired factors like inflammation or a developmental disorder, although the definitive etiology is unknown ^[4].

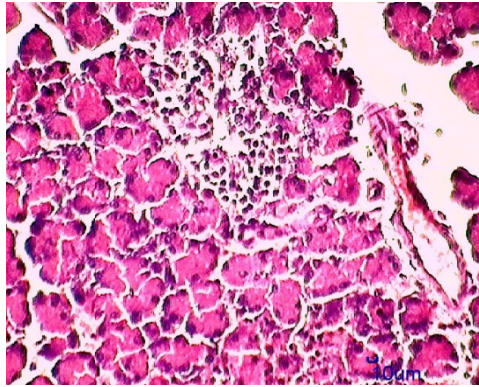


Figure 4. Pancreas (inside herniated mass) showing decreased cellularity, mild mononuclear cell infiltration along with mild hemorrhage. H&E x 100.

Peritoneal injury, infection or irritation, initiates an inflammatory reaction that increases all components of the peritoneal fluid, i.e., proteins and cells, generating fibrous exudates and the formation of fibrin. Fibrin formation is the result of the activation of the coagulation cascade. These fibrinous exudates and fibrin deposition are an essential part of normal tissue repair. The mesenteric cyst histopathologically showed a single layer of flattened mesothelial cells. The exact aetiology or formation of solitary cyst containing transparent serous fluid in mesentery had yet to be ascertained. However, the hernial mass showed mild inflammatory reaction which could be due to the inflammatory response which was seen induced in case of hernial repair^[5].

CONCLUSION

The histopathological findings of liver showed a focal area of hypertrophied hepatocytes, which might have been shown in response to pressure or to impairment of blood or bile flow.

High energy diets lead to obesity and also serve as a drive for higher body weight. Weakness of abdominal muscles by infiltration of fat can cause gradual stretching apart of the whole abdominal musculature along the linea alba, which could lead to the protrusion of organs^[6]. Intestinal herniation in birds could be treated if recognized earlier. Further studies need to be implemented to study the pathogenesis of herniation in birds.

REFERENCES

1. Parrah JD, et al. Surgical management of abdominal hernia in a duck (*Anas platyrhynchos*). *Mathews J Vet Sci.* 2016;1:002.
2. Haridy M, et al. Herniation of duodenum into the right ventral hepatic peritoneal cavity with groove formation at the ventral hepatic surface in a 2-week-old chicken. *J Vet Med Sci.* 2013;75:1405-1407.
3. Bancroft JD and Gamble M. *Theory and practice of histological techniques.* 6th edition, 2008, Elsevier, Philadelphia.
4. Smolec O, et al. Abdominal ventral hernia in a pigeon (*Columba livia*): a case report. *Veterinari Medicina.* 2009;54:291- 294.
5. Di Vita G, et al. Acute inflammatory response after inguinal and incisional hernia repair with implantation of polypropylene mesh of different size. *Langenbecks Arch Surg.* 2005;390:306- 311.
6. Wohlsein P and J Saliki. *Rinderpest and Peste des Petits ruminants-the diseases: Clinical signs and Pathology.* Rinderpest and Peste des Petits Ruminants, Elsevier. 2006;68.