

## Oncoplastic Surgery of Multicentric (Multifocal) Breast Cancer

Irakli Kokhreidze\*

Department of Oncology, First University Clinic of Tbilisi State Medical University (TSMU), Tbilisi, Georgia

### Case Report

Received date: 14/09/2017

Accepted date: 24/09/2017

Published date: 03/10/2017

#### \*For Correspondence

Irakli Kokhreidze, Department of Oncology, First University Clinic of Tbilisi State Medical University (TSMU), Tbilisi, Georgia, Tel: +995 599548812

**E-mail:** i.kokhreidze@gmail.com

**Keywords:** Multicentric/multifocal breast, Cancer, Oncoplastic breast surgery

#### ABSTRACT

The multicentric/multifocal form of breast cancer has been considered as relative contraindication for breast conserving surgery. According to the results of the studies conducted in the last century, the local recurrence rate of the disease after breast conserving surgeries of multicentric/multifocal breast cancer exceeds 40%. Thus these data were considered as main argument for mastectomy advocates, as non-alternative surgical treatment in these cases. Wide clinical application of oncoplastic surgical techniques gave us possibilities to resolve dilemma: excise tumor - containing quadrant with achieving clear margins and satisfactory cosmetic outcome, without increasing risk of disease-related complications. In cases of multicentricity/ multicocality of breast cancer, total axillary lymphadenectomy might be avoided when size of tumor is less than 2 cm and there are no signs of malignant involvement of axillar lymph nodes; In case of clinically negative axillary lymph nodes – sentinel lymph node biopsy might be the standard option. Of course, adjuvant treatment should be planned in accordance with the principles of personalized medicine, based on the results of multidisciplinary review and taking into consideration modern advanced guidelines and recommendations.

### INTRODUCTION

The breast-conserving treatment, in essence, implies not only providing breast-conserving surgery (BCS), but also adjuvant radiation therapy, that significantly reduces the risk of disease loco-regional and distant recurrence and is considered as an integral part of breast cancer conservative treatment [1,2]. Traditionally, appearance of more than one malignant tumor, in one or several breast quadrants, might be referred to as multifocal and multicentric breast cancers (MMBC). In addition, multifocal lesions localized in one quadrant of the breast are commonly referred to as multifocal cancers and multifocal lesions of different quadrants of the same or both breasts – multicentric cancers, respectively [3-5]. Such difference in definitions might be caused by different morphogenesis of tumor growth: in case of multifocal cancer, multiple tumors originate within an intraductal system of one quadrant, while at multicentric cancer, several focuses of tumor growth, appear in the intraductal system of different quadrants. Consequently, it can be concluded that, multifocal cancer is a monoclonal disease rather than multicentric [6].

According to Tot et al. [7] several scenarios causing occurrence of multicentre cancer should be considered:

- Intra-organic spread of the cells from one malignant lesion to different quadrants of the breast.
- In one or both breasts – simultaneous appearance from different zones of malignant transformation.
- Extensive intraductal component (EIC) - as the initial stage and primary source of the disease multicentricity/multifocality [7].

Hitherto, the multicentric/multifocal form of breast cancer has been considered as relative contraindication for breast conservative surgery, based on the following:

1. Multicentric breast cancer – it is a malignant disease of the breast with more aggressive nature.
2. In case of multicentricity, the rate of local relapse after conserving surgery is much higher, than after mastectomy.
3. Benefit from adjuvant radiotherapy in case of multicentric disease is much more less.
4. Actually, after conservative surgery of multicenter breast cancer, it is impossible to achieve cosmetically "satisfactory" results [8].

## Research and Reviews: Reports in Cancer and Treatments

Thus, conceptually, universally recognized standard of breast conservative treatment – providing oncological adequate surgery with achievement of satisfactory cosmetic effect would be in jeopardy. According to the results of the studies conducted in the last century, the local recurrence rate after breast conserving surgeries for multicentric disease exceeds 40%. Thus these data were considered as main argument for mastectomy advocates, as non-alternative surgical treatment in these cases<sup>[9]</sup>. According to the data recorded by FE Vera-Badillo et al.<sup>[10]</sup>, R Wolters et al.<sup>[11]</sup>, and AP Chung et al.<sup>[12]</sup>, the prevalence of multicentric breast cancer varies within 5.2%- 15.8%. Using the “gold standard” of diagnostic options for this disease – magnetic resonance imaging (MRI) of the breast, sharply increases degree of disease spread<sup>[10-12]</sup>. Meta-analysis of the studies conducted by N Haussami et al. have showed that in the case of clinical unilateral breast cancer MRI imaging increases the detection of occult primary tumor rate by almost 16%. In addition, MRI is characterized with high frequency of so-called, false-positive responses: consequently, after morphological examination about 1/3 of suspicious lesions, appear to be benign<sup>[13]</sup>. The high rates of false-positive findings, in turn, have a negative impact on the quality of treatment, which is caused with 25% conversion to mastectomy, in cases when the main primary option of surgery was breast conservation<sup>[14]</sup>. The need in changing of traditional approaches and, especially, the possibility of conservative treatment of multicentric breast cancer - in terms of technical progress, improving the quality of treatment modalities and principally new understanding of breast cancer "natural history" - seem to be logical. According to data, obtained by R. Wolters et al., in cases of multicentric breast cancer the overall survival rate is the same in the groups, whom breast conserving surgery or mastectomy had been provided, which allows offering breast conservation surgery to all patients with stage T1/T2 multicentric (multifocal) disease, as a possible and safe option<sup>[11]</sup>. According to data recorded by W Lim et al. in the case of unicentric and/or multicentric cancer, after breast conserving surgeries the local recurrence rates do not differ from each other<sup>[14]</sup>. A large retrospective analysis conducted by G Gentilini et al., showed that, breast-conserving surgery (BCS) might be a safe alternative of mastectomy for multicentric (multifocal) breast cancer, in cases when negative surgical margins have been achieved during surgery, followed by adjuvant therapy (chemotherapy, immunotherapy, radiotherapy or endocrine therapy) in post-operative period<sup>[15]</sup>.

### CASE PRESENTATION

Patient – MS. 35 of age, applied to the Oncology Department of TSMU First University Clinic on 27/06/2017, complaining of multiple nodularity in her left breast. By ultrasonography - an uneven shape tissue structural formation, 4 x 3 mm in size with decreased echogenicity has been revealed at 6 mm deep from the skin on 5 h projection have seen in the lower lateral quadrant of the left breast. The formation of similar structure 3.5 x 3 mm in size was reflected at the border of lower quadrants of the same breast at 6 mm deep. The lymph node of unchanged echo structure and 2 mm in diameter was revealed in the left axillary fossa. Echography image corresponds to the multicentric cancer of the left breast. According to mammography – two nodular formations with increased intensity, uneven shape and 5 x 4 mm and 4 x 4 mm in sizes were reflected on the border of lower lateral and lower quadrants in the left breast. Left breast multicentric cancer was suspected. Ductal epithelial cells with expressed proliferation and signs of cellular polymorphism corresponding to ductal carcinoma were seen on the background of intracellular and adipose substances after FNA - biopsy and cytological examination of punctate. It should be emphasized, that the patient underwent ultrasound and mammography, with biopsy as well as breast units' health care providers at the several oncological clinics of Tbilisi. Colleagues divided in opinion: radical mastectomy or mastectomy – with nipple - areola sparing (NASM) complex, with or without immediate breast reconstruction has been offered.

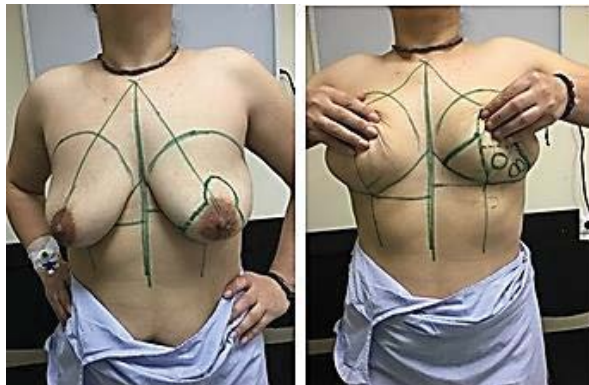
The examination of the patient conducted at TSMU First University Clinic showed that the woman has given birth (2 physiological labors), lactation lasted for 1 year and there was no personal oncologic or familial predisposition. By inspection: mammary glands are symmetric, ptosis expressed (Grade 3), volume corresponds to E (cup) size, visually - without pathology. Nipple - areola complexes are of symmetric locations and visually unchanged. By palpation: a tumor formation with restricted range of motion, uneven surface, dense-rough consistency and 1.5 x 1.5 cm in size was palpated on the border of the left breast lower quadrants. Two interdependent formations with similar signs were revealed in the lower-outer quadrant of the same breast (sizes: 1.0 x 1.0 cm and 1.0 x 0.5 cm). No lesion was observed in the right breast of patient. Regional zones bilaterally were without any pathology. Magnetic resonance imaging (MRI) of the breast was performed. On the obtained tomograms, areolas and skins of both mammary glands unchanged and the structures of both glands non-homogenous with abundance of adipose tissues. Single cystic zones producing hyper intense (T2se) signals, with straight, clear contours and 0.5 cm of sizes were reflected in both mammary glands. By the first type of contrast, in accordance with the MRI data, it corresponds to fibro-cystic changes; the largest - on the left, on the border of lower quadrants 1.5 cm of size and 3.6 cm distance from the skin.

In this background, two volumetric formations of nonhomogeneous structures, flash-contoured, 0.9 cm and 1.0 cm of sizes, in 1,7 cm and 2,2 cm distances from the skin, were reflected on the lower lateral quadrant projection in the left breast. By subtraction they remain contrasted. For both formations, a second type of diagram is characteristic, which, according to the conclusion, is characteristic of a low degree of malignancy and a correlation with the results of morphological investigation is required. After using intravenous contrast in the right breast, no pathological involvement of contrast medium was revealed. Both axillary regions are without pathological changes.

## Research and Reviews: Reports in Cancer and Treatments

### Surgery Planning

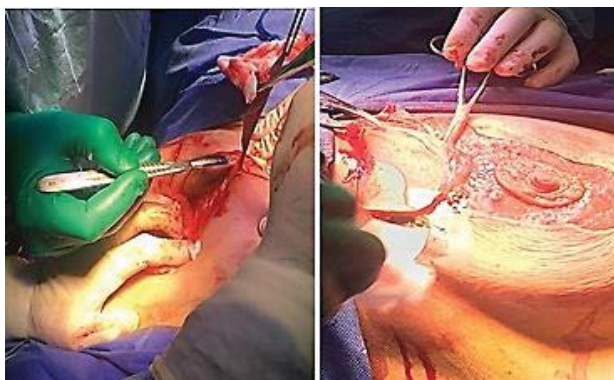
The oncoplastic quadrantectomy (Wise pattern mammoplasty, with the blood supply for the NAC on the upper flap), with axillary lymphadenectomy was scheduled. Pre-operative markings were performed in the standing position of the patient. Have been performed markings of sternal line, meridians of mammary glands, sub mammary folds and localizations of basic tumoral nodes in the left breast (**Figures 1 and 2**).



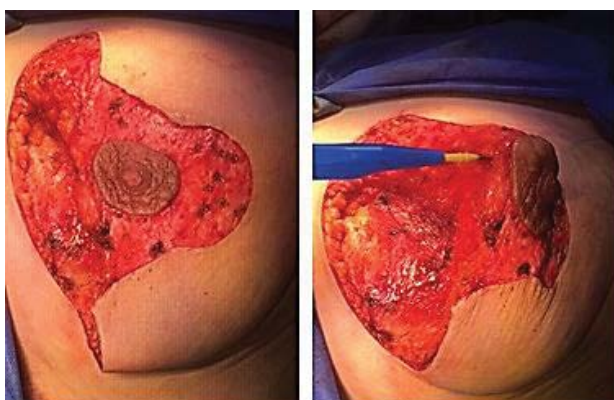**Figure 1.** Pre-operative markings.

The incisions along the preoperative marking lines were made under general anaesthesia. The initial stage of the surgery was mobilization of tumor containing quadrant, requiring the de-epithelialization of skin area of pre-determined size. Then, mobilization of the quadrant injured by lesions and its further removal has been conducted. The quadrant resection margins were marked and the material was sent for the morphological study, which identified the "negative" tumor margins. The wound was washed out with antiseptic solutions; haemostasis was achieved by coagulation and ligation of medium-calibre blood vessels (**Figure 2**).

The next stage in the mentioned surgery was the oncoplastic closure of the postoperative defect (**Figure 3**), with cranial transposition of the nipple-areola complex. After clipping the resection cavity margins (in order to facilitate identification of future irradiation zone area) two vertical incisions were done in the periareolar, de-epithelialized zone, so that to allow the formed sprout to promote shifting of nipple-areola complex upward (**Figure 4**).

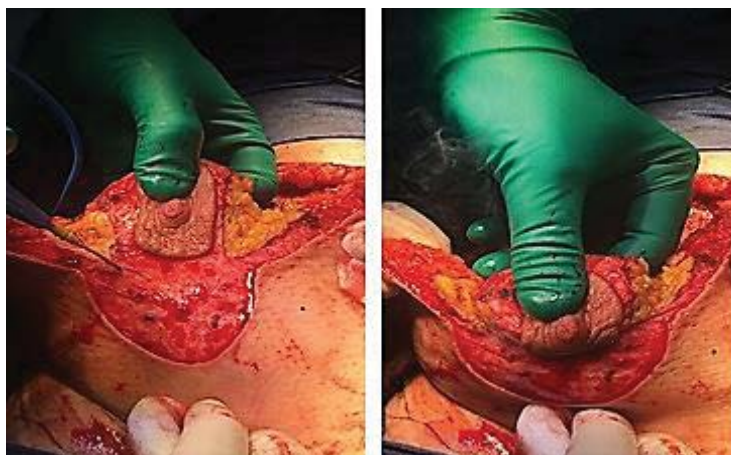

**Figure 2.** Periareolar, de-epithelialization, mobilization and removal of quadrant containing lesions.



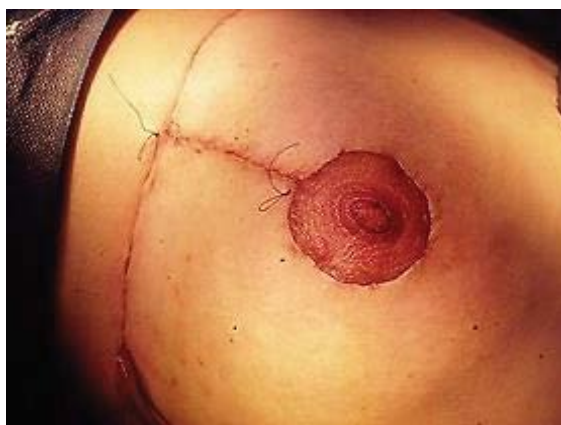**Figure 3.** Left breast after quadrantectomy, de-epithelialization zone and post-resection defect.





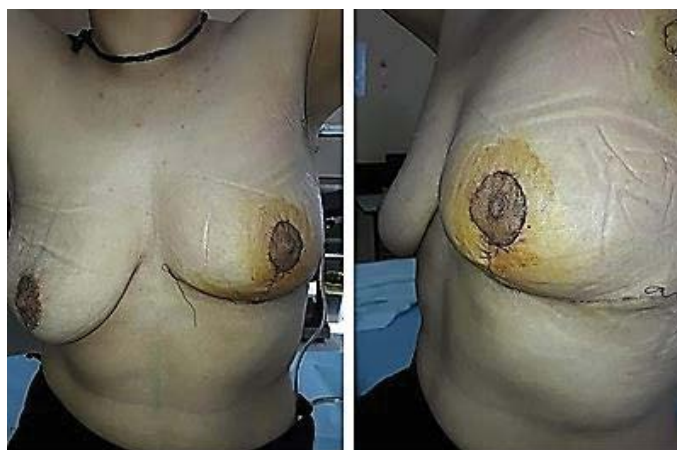**Figure 4.** Nipple - areola complex (NAC) mobilization.

Breast remodelling was performed using situational and sub dermal stitches so that the resulted scar replicated the shape of an inverted "T" (**Figure 5**). Additional incision made in the axillary fossa, facilitated approach to the lymphatic collectors of I-II-III levels which were removed end block. The axillary fossa was drained, the wound were treated with antiseptic solutions and sutured by using subcuticular, continuous stitches (**Figure 6**).



**Figure 5.** Operated breast after remodelling and closure.

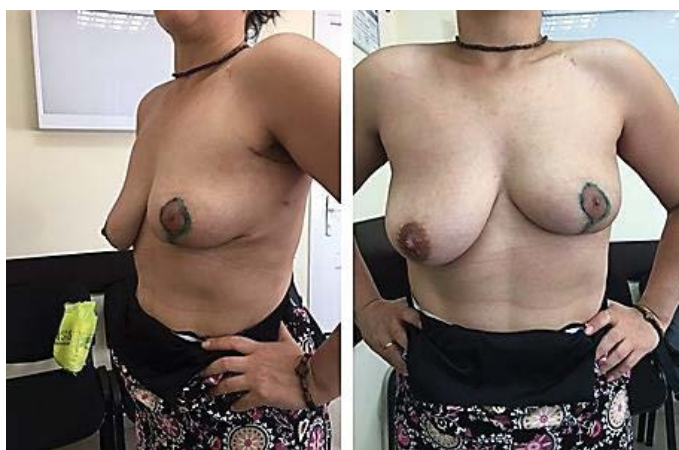According to morphological examination (#3988) no tumor lesions were revealed along the resection margins of removed tissues. In the damaged part removed from the left breast, multifocality was noted - 3 different tumor nodes (11 mm, 8 mm, 10 mm in size), identified as invasive ductal carcinomas, were revealed. The degree of differentiation was GII - with *in situ* component, in which the differentiation rate GII, also was revealed. It should be noted that lymphangiogenesis was observed, but perineural invasion was not seen. No metastatic lesions were found in any of the studied 19 lymph nodes. According to the results of immunohistochemical study, the disease proved to be hormone-sensitive (ER<sup>+</sup>, PR, Her2/neu1<sup>+</sup>), Ki 67.5%.



**Figure 6.** 12 days after surgery.

### RESULTS AND DISCUSSION

Breast conserving surgery was performed in full compliance with oncoplastic principles of surgical oncology. All malignant lesions within the one quadrant have been removed. Have been achieved negative resection margins - which is the main task of these types of operations. During the surgery, axillary lymph nodes of I-II-III levels were removed through the additional incision. A satisfactory cosmetic outcome achieved by the oncoplastic surgery stipulates high or excellent ratings of patient satisfaction. A noticeable shape difference between mammary glands (**Figure 7**) observed in the postoperative period might become more visible after the adjuvant radiation therapy due to radiation epitheliitis and fibrosis, which is why one-moment symmetrizing surgery is always avoided and is performed only in 6-12 months after the first surgical intervention (**Figure 7**).



**Figure 7.** A month after surgery.

The lesions were healed with residual initial strains, the sarcoma formation was moderate, and drainage tube was removed on the 12th day after surgery. To minimize the risk of local and systemic recurrence of the disease and due to the young age of the patient as well as immune-morphological features of the disease, providing adjuvant chemotherapy and ovarian ablation (6 cycles of anthracycline-containing cycles + Goserelin) followed by adjuvant radiation therapy and then adjuvant endocrine therapy according to NCCN, ESMO, ASCO guidelines was recommended.

### CONCLUSION

For multicentric/multifocal breast cancer, breast conservative surgical interventions can be performed instead of mastectomy, which was considered as non-alternative method for treatment of malignant tumors of this type. In cases of multicentricity/multicocality of breast cancer, total axillary lymphadenectomy might be avoided when size of tumor is less than 2 cm and there are no signs of malignant involvement of axillary lymph nodes; In case of clinically negative axillary lymph nodes – sentinel lymph node biopsy might be the standard option. Adjuvant treatment should be planned in accordance with the principles of personalized medicine, based on the results of multidisciplinary review and taking into consideration modern advanced guidelines and recommendations.

### REFERENCES

1. Veronesi U. Twenty-year follow-up of a randomized study comparing breast-conserving surgery with radical mastectomy for early breast cancer. *N Engl J Med.* 2002;347:1227–1232.
2. Zurrida S, et al. The Veronesi quadrantectomy: an established procedure for the conservative treatment of early breast cancer. *Int J Surg Investig.* 2001;2:423–431.
3. Lagios MD, et al. The concept and implications of multicentricity in breast carcinoma. *Pathol Annl.* 1981;16:83–102.
4. Boyages J, et al. Multifocal breast cancer and survival: each focus does matter particularly for larger tumours. *Eur J Cancer.* 2010;46:1990–1996.
5. Mahul BA. *AJCC Cancer Staging Manual.* 8<sup>th</sup> edition, 2016.
6. Noguchi S, et al. Discrimination between multicentric and multifocal carcinomas of the breast through clonal analysis. *Cancer.* 1994;74:872–877.
7. Tot T, et al. Breast cancer multifocality, disease extent, and survival. *Hum Pathol.* 2011;42:1761-1769.
8. Nijenhuis MV and Rutgers EJ. Conservative surgery for multifocal/multicentric breast cancer. *The Breast.* 2015;24:S96-S99.

## Research and Reviews: Reports in Cancer and Treatments

9. Elshof LE, et al. A practical approach to manage additional lesions at preoperative breast MRI in patients eligible for breast conserving therapy: results. Springer US. *Breast Cancer Res Treat.* 2010;124:707-715.
10. Vera-Badillo FE, et al. Effect of multifocality and multicentricity on outcome in early breast cancer: a systematic review and meta-analysis. *Breast Cancer Res Treat.* 2014;146:235-244.
11. Wolters R, et al. Comparing the outcome between multicentric and multifocal breast cancer: what is the impact on survival, and is there a role for guideline-adherent adjuvant therapy? A retrospective multicenter cohort study of 8935 patients. *Breast Cancer Res Treat.* 2013;142:579-590.
12. Chung AP, et al. Comparison of outcomes of breast conserving therapy in multifocal and unifocal invasive breast cancer. *J Am Coll Surg.* 2012;215:137-147.
13. Houssami N, et al. Accuracy and surgical impact of magnetic resonance imaging in breast cancer staging: systematic review and meta-analysis in detection of multifocal and multicentric cancer. *JH Clin Oncol.* 2008;26:3248-3258.
14. Lim W, et al. Breast conserving surgery for multifocal breast cancer. *Ann Surg.* 2009;249:87-90.
15. Gentilini O, et al. Conservative surgery in patients with multifocal/multicentric breast cancer. *Breast Cancer Res Treat.* 2009;113:577-583.