

Research and Reviews: Journal of Dental Sciences

Sealing The Communication with MTA- Case Series

Rashi Agrawal^{1*}, Arpan Pavaiya¹, Chandrakar Chaman Mishra²

¹Kalka Dental College, Uttar Pradesh, India

²Kothiwal Dental College, Uttar Pradesh, India

Case Report

Received: 21/06/2016

Accepted: 30/06/2016

Published: 07/07/2016

*For Correspondence:

Rashi Agrawal, 26 Jain Medical Centre, Mall Road, Ahinsa Khand 2, Indrapuram, Ghaziabad, Uttar Pradesh, 201014, India, Tel: 8588076706

E-mail: jainmedicalcentre26@gmail.com

Keywords: MTA, Calcium hydroxide, Root resorption, Apical plug, Non-surgical healing.

INTRODUCTION

Root resorptions are characterized by progressive loss of tooth substance caused by transformation of normal pulp tissue into granulomatous tissue with giant cells, which resorb root dentin and later bone. This transformation is thought to stem from chronic inflammation of the pulp caused by continuing bacterial stimulation.

Apical external inflammatory root resorption is among all types of resorption, the one that is most frequently observed in clinical practice. It is seen in cases as a late sequel of traumatic injuries, orthodontic movement, or chronic pulpal or periodontal infection [1].

The mineral trioxide aggregate (MTA) well known for its great biocompatibility, has demonstrated excellent sealing ability in studies of dye penetration and bacterial leakage even under blood contamination conditions [2-4]. It has been used widely in treatment of resorptions, especially when there is communication with the periodontium as it induce regeneration of periradicular tissues such as bone and cementum.

MTA has properties such as a good sealing, biocompatibility, radiopacity, regenerative capacity for periradicular tissues, such as bone and cementum and also does not suffer alterations in the presence of humidity.

The present case reports demonstrate non-surgical therapy of external root resorption and the use of MTA as an apical plug to promote periapical healing.

CASE REPORT

Case 1

An 18 year old male patient reported to clinic with the chief complaint of pain in the upper right back region of the jaw. Clinical examination revealed extensive occlusal caries in relation to 16. The tooth did not respond to any sensibility tests [EPT and Cold Test] although it was sensitive to percussion.

Radiographic examination showed radiolucency involving enamel dentin pulp and resorption of the distobuccal root (Figure 1).

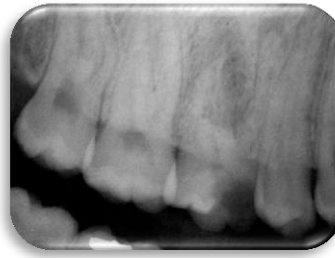


Figure 1. Preoperative case 1.

Case 2

A 35 years old female patient reported to the clinic, with a complaint of a discolored tooth in the upper front region of the jaw. Clinical examination revealed a discolored and Grade 1 mobile 21, which did not respond to any sensibility tests [EPT and Cold Test]. The tooth was not sensitive to percussion.

Radiographic examination revealed resorption of the root apex, localized bone loss and widening of the periodontal ligament space as in **(Figure 2)**.

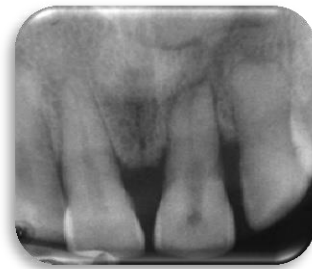

Figure 2. Preoperative case 2.

Case 3

A 35 year old male patient reported to the clinic with the chief complaint of pain in the upper left back region of the jaw. Clinical examination revealed extensive occlusal caries in relation to 24. The tooth did not respond to any sensibility tests [EPT and Cold Test] but was sensitive to percussion. Radiographic examination showed resorption of the root as in **(Figure 3)**.

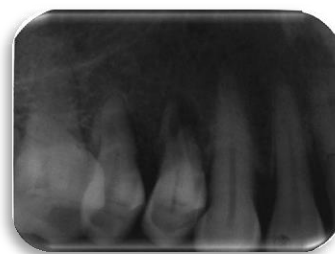


Figure 3. Preoperative case 3.

PROCEDURE

Conventional root canal treatment was performed where canals were debrided and irrigated with 2.5% sodium hypochlorite solution and saline. Pure calcium hydroxide was mixed with distilled water and placed in canal. In

consecutive sitting when canal were cleaned and no discharge was visible, canal were dried with sterilized paper points. MTA powder was mixed with distilled water and packed into 4mm of apical end as an apical plug. A wet cotton was placed in canal for 24 hours to maintain high humid environment. In case 1 first obturation was done in other canals and then MTA plug was given in consecutive sitting (**Figure 4**).

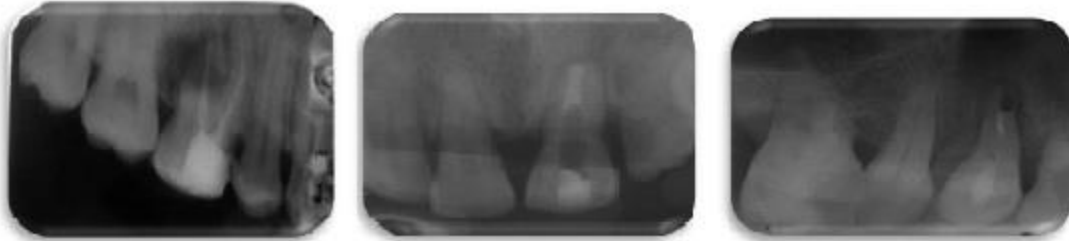

Figure 4. Post obturation for other canal (case 1) post MTA PLUG (case 2,3).

After MTA has set, we filled the residual canal space with gutta-percha (Figure 5). Final restoration of composite restoration was done.

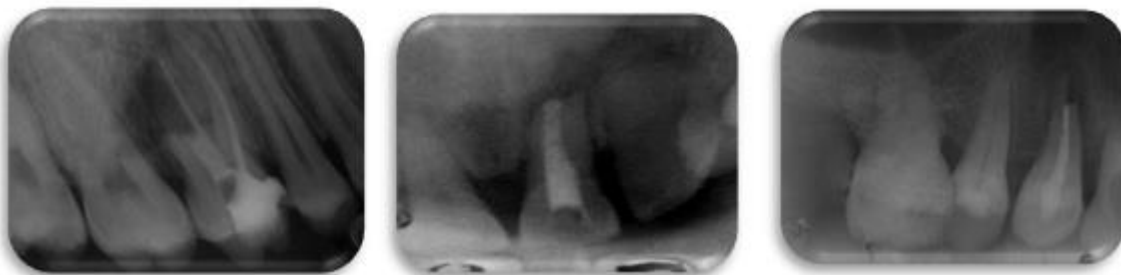

Figure 5: Post MTA plug and obturation (case 1,2,3).

After 5 month follow-up, patients were asymptomatic. Clinical examination showed no signs of edema, erythema or sinus tracts, teeth were non sensitive to percussion and palpitation, and all probing depths were within normal limits. Radiographic examination showed arrested resorption and healing radiolucent periapical lesion (Figure 6).

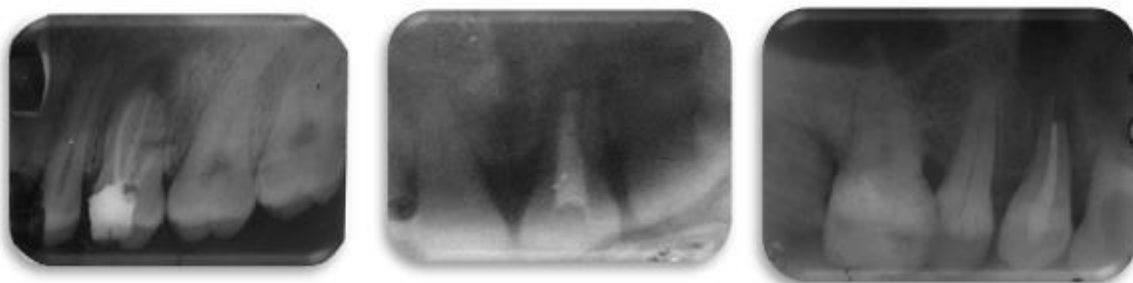


Figure 6: Follow up after 5 months (case 1,2,3).

DISCUSSION

- External inflammatory tooth resorption is a complex process occurring due to the removal of the organic and inorganic components of tooth structure by clastic cells.

- In order for root resorption to occur:
 1. Loss or alteration of the protective layer of cementum and periodontal ligament.
 2. Inflammation must occur on the unprotected root surface (due to high concentration of bacteria and their byproducts in that area).
- Treatment of inflammatory resorption is based on removal or reduction of the source of infection [5]. Non-surgical root canal therapy with the use of calcium hydroxide as an intra-canal medicament is recommended [6]. In this case, arrest of the external resorption and induction of apical closure guided the treatment plan.
- The purposes of calcium hydroxide dressing were
 1. Disinfection
 2. Creation of a physicochemical barrier
 3. The inhibition of bacterial enzymes leading to an antimicrobial effect
 4. The activation of tissue enzymes leading to a mineralizing effect by maintaining the root canal at high pH value; an environment suitable for hard tissue formation and MTA setting [7].

These cases represent an example of inflammatory apical root resorption caused by pulpal necrosis that occurred due to long standing caries. Infection induced tooth resorption requires the removal of the invading microorganisms by endodontic therapy and placement of an intra-canal medicament which can also facilitate repair of the resorbed tooth structure.

Most challenging aspect of management in these cases is to obtain a good apical seal that has been lost due to resorbed apical matrix.

Mineral trioxide aggregate (MTA) principal components include tricalcium silicate, tricalcium aluminate, tricalcium oxide and silicate oxide which due to hydrophilic nature set in presence of blood and moisture. Hydration of the powder produces a colloidal gel with a pH of 12.5 that solidifies into a hard structure in 165 ± 5 minutes. MTA provides a biologically active substrate for cell attachment thereby making it effective in preventing micro leakage and improving the treatment prognosis.

MTA can be used to stimulate hard tissue formation on resorbed root surfaces and to create superior apical seal more than materials such as amalgam, IRM, gutta-ercha, and Super EBA [8]. Effective sealing ability in vitro of 4 mm thickness is most adequate for MTA as root end filling material [9]. MTA, when used as a root-end filling material, showed evidence of healing of the surrounding tissues [10-12]. Most characteristic tissue reaction of MTA was the presence of connective tissue after the first postoperative week [13]. Studies have shown that osteoblasts have favorable response to MTA as compared to IRM and amalgam. With longer duration, new cementum was found on the surface of the material [14]. In a two year follow-up study with MTA as root-end filling material resulted in a high success rate [15].

MTA has been shown to be osteoconductive and promote osteogenesis when implanted intraosseously [16]. Cementogenesis in the presence of MTA has been evaluated by assessment of the expression of the osteocalcin (OCN), cell growth and the morphology of the cementoblast like cells. SEM analysis indicated that cementoblasts could attach and grow on MTA [17].

MTA can induce biological responses in osteoblastic cells due to adhesion [14], increasing cytokines [18,19] and osteocalcine production [18]. Osteocalcine is the most found non-collagenic protein characteristic of osteoblast synthesis, and can be used as an indicator of matrix production. Thus, MTA presents a biologically active substrate

for bone cells and stimulates the production of interleukines [20]. However, according to Moretton et al. [16], MTA is not osteoinductive (does not induce the differentiation of cells that produce bone tissue in tissues where bone is not present, such as connective tissue) but is only osteoconductive (stimulates the production of mineralized tissue in areas where this tissue is normally present).

It should be emphasized that the favorable results found when applying MTA are due to its biocompatibility, antibacterial activity and stimulation of mineralized tissue deposition, which stimulate the healing process.

CONCLUSION

A correct diagnosis and an understanding of the etiology and dynamics of the processes involved in tooth resorption is critical to effective management.

Despite the damage to the tooth due to external root resorption, non-surgical root canal therapy can arrest the resorptive process and can promote the regeneration of periapical tissues thereby promoting healing.

REFERENCES

1. Benanti FW. Root resorption types and treatment. *Gen Den.* 1997;45:42-45.
2. Lee SJ, et al. Sealing ability of a mineral trioxide aggregate for repair of lateral root perforations. *J Endod.* 1993;12:541-544.
3. Torabinejad M, et al. Bacterial leakage of mineral trioxide aggregate as a root end filling material. *J Endod.* 1995;21:109-112.
4. Torabinejad M, al. Dye leakage of four root end filling materials: effects of blood contamination. *J Endod.* 1994;20:159-166.
5. Bakland JK. Root resorption. *Dental Clin North Am.* 1992;36:491-507.
6. Andreasen AF. *Textbook and color atlas of traumatic injuries to the teeth.* Mosby, St. Louis. 1994.
7. Lee YI, et al. Effects of physiological environments on the hydration behavior of mineral trioxide aggregate. *Biomaterials.* 2004;25:787-793.
8. Torabinejad M, et al. Sealing ability of a mineral trioxide aggregate when used as a root end filling material. *J Endod.* 1993;19:591-595.
9. Valois CR and Costa ED. Influence of the thickness of mineral trioxide aggregate on sealing ability of root end filling in vitro. *Oral Surg Oral Med Oral Pathol Oral Radiol Endod.* 2004;97:108-111.
10. Torabinejad M, et al. Comparative investigation of marginal adaptation of mineral trioxide aggregate and other commonly used root end filling materials. *J Endod.* 1995;21:295-299.
11. Torabinejad M, et al. Investigation of mineral trioxide aggregate for rootend filling in dogs. *J Endod.* 1995; 21:606-608.
12. Torabinejad M and Pitt Ford TR. Root end filling materials-a review. *Endodont Dent Traumotol.* 1996;12: 161-178.
13. Economides N, et al. Short-term periradicular tissue response to mineral trioxide aggregate (MTA) as root-end filling material. *Int Endod J.* 2003;36:44-48.
14. Qiang Zhu, et al. Adhesion of Human Osteoblasts on Root-End Filling Materials. *J Endod.* 2000; 27:404-406.

15. Chong BS, et al. A prospective clinical study of Mineral Trioxide Aggregate and IRM when used as root-end filling materials in endodontic surgery. *Int Endod J.* 2003;36 520-526.
16. Moretton TR, et al. Tissue reactions after subcutaneous and intra osseus implantation of mineral trioxide aggregate and ethoxybenzoic acid cement. *J Biomed Mater Res.* 2000;52:528-533.
17. Torabinejad M, et al. Physical and chemical properties of a new root-end filling material. *J Endod* 1995;21:349-353.
18. Koh ET, et al. Mineral trioxide aggregate stimulates a biological response in human osteoblasts. *J Biomed Mater Res.* 1997;37:432-439.
19. Mitchell PJ, et al. Osteoblast biocompatibility of mineral trioxide aggregate. *Biomaterials.* 1999;20:167-173.
20. Koh ET, et al. Cellular response to mineral trioxide aggregate. *J Endod.* 1998;24:543-547.